Instructors may assign a portion of the Review Sheet questions using Mastering A&P™

EXERCISE 10 REVIEW SHEET

The Appendicular Skeleton

Name: Shani MSIntyre Lab Time/Date _____

Bones of the Pectoral Girdle and Upper Limb

1. Fill in the blank to complete the statements below:

   a. The bones that form the pectoral girdle are the Clavicle and Scapula.

   b. The upper limb is formed by the arm bone, the humerus, and the two bones of the forearm, the Ulna and radius.

   c. The carpals are the wrist bones. List the proximal row of wrist bones from lateral to medial: Scaphoid, lunate, Triquetrum, Pisiform

   List the distal row of wrist bones from lateral to medial: Trapezium, Trapezoid, Capitate, hamate

   d. The metacarpals form the palm of the hand, and the heads of these bones form the knuckles.

   e. A single finger bone is called a Phalanx. Each hand has 14 finger bones, called Phalanges.

2. Match the bone markings in column B with the descriptions in column A.

Column A		Column B
F	1. depression in the scapula that articulates with the humerus	a. acromion
K	2. surface on the radius that receives the head of the ulna	b. capitulum
B	3. lateral rounded knob on the distal humerus	c. coracoid process
H	4. posterior depression on the distal humerus	d. coronoid fossa
E	5. a roughened area on the lateral humerus: deltoid attachment site	e. deltoid tuberosity
C	6. hooklike process; biceps brachii attachment site	f. glenoid cavity
I	7. surface on the ulna that receives the head of the radius	g. medial epicondyle
J	8. medial condyle of the humerus that articulates with the ulna	h. olecranon fossa
A	9. lateral end of the spine of the scapula; clavicle articulation site	i. radial notch
G	10. small bump on the humerus, often called the "funny bone"	j. trochlea
D	11. anterior depression, superior to the trochlea, that receives part of the ulna when bending at the elbow	k. ulnar notch

3. Using items from the list at the right, identify the anatomical landmarks and regions of the scapula.

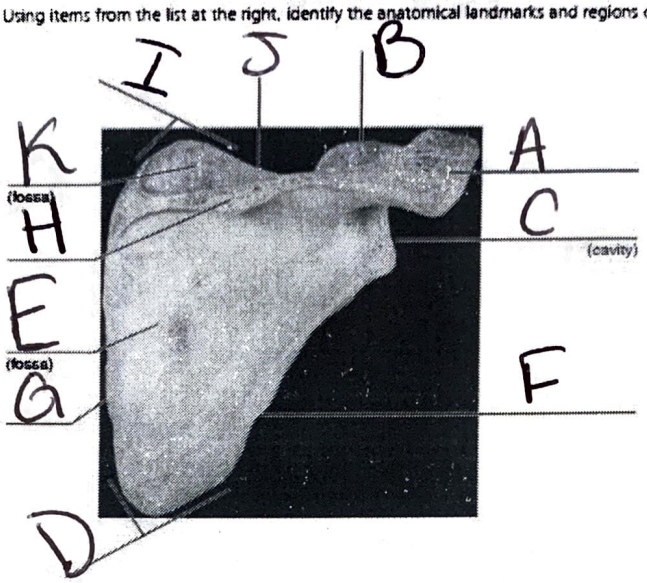

Key:

a. acromion
b. coracoid process
c. glenoid cavity
d. inferior angle
e. infraspinous fossa
f. lateral border
g. medial border
h. spine
i. superior angle
j. superior border
k. supraspinous fossa

4. Match the terms in the key with the appropriate leader lines on the photograph of the humerus.

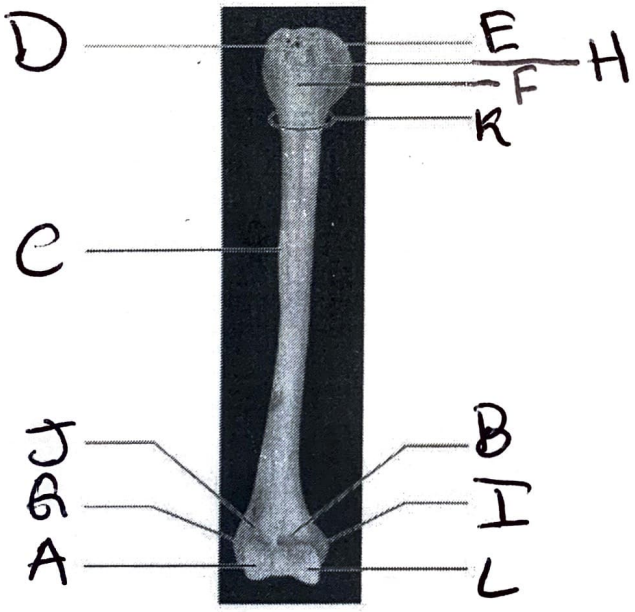

Key:

a. capitulum
b. coronoid fossa
c. deltoid tuberosity
d. greater tuberde
e. head
f. intertubercular sulcus
g. lateral epicondyle
h. lesser tuberde
i. medial epicondyle
j. radial fossa
k. surgical neck
l. trochlea

5. Match the terms in the key with the appropriate leader lines on the photographs of the posterior view of the radius on the left and the lateral view of the ulna on the right.

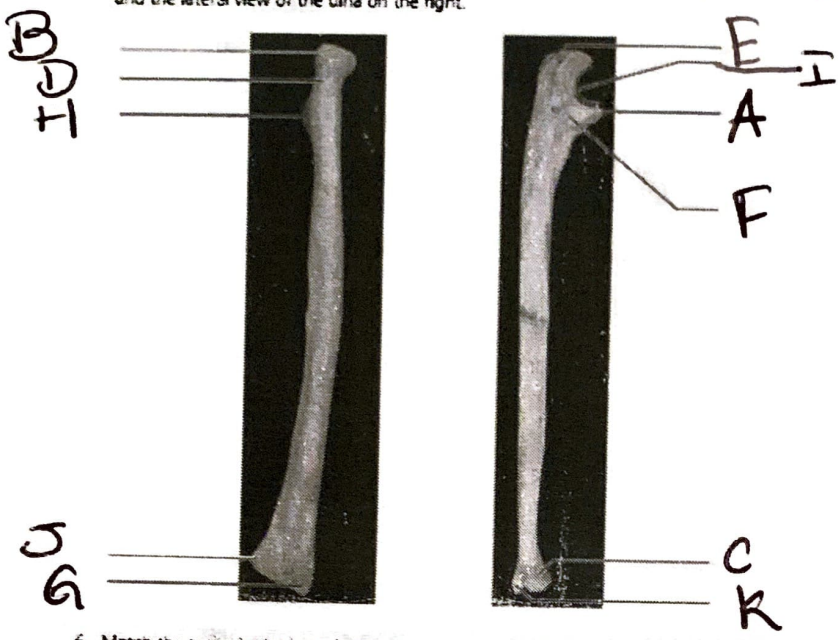

Key:

a. coronoid process
b. head of the radius
c. head of the ulna
d. neck of the radius
e. olecranon
f. radial notch of the ulna
g. radial styloid process
h. radial tuberosity
i. trochlear notch
j. ulnar notch of the radius
k. ulnar styloid process

6. Match the terms in the key with the appropriate leader lines on the photograph of the anterior view of the hand.

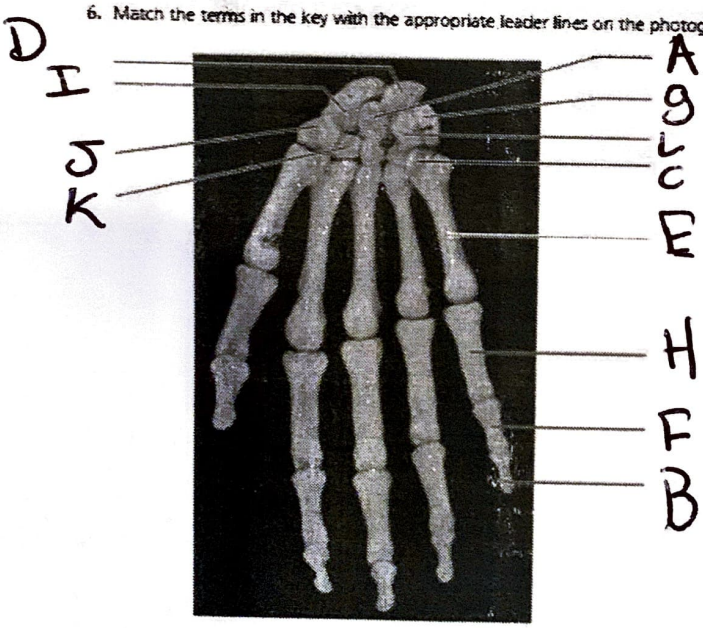

Key:

a. capitate
b. distal phalanx
c. hamate
d. lunate
e. metacarpal
f. middle phalanx
g. pisiform
h. proximal phalanx
i. scaphoid
j. trapezium
k. trapezoid
l. triquetrum

7. Name the two bone markings that form the proximal radioulnar joint

The radial notchof ulna and the head of radius

8. Name the two bone markings that form the distal radioulnar joint

The annular ligament and the ulnar radical notch

Bones of the Pelvic Girdle and Lower Limb

9. Compare the pectoral and pelvic girdles by choosing appropriate descriptive terms from the key

Key:
a flexibility most important
b massive
c lightweight
d insecure axial and limb attachments
e secure axial and limb attachments
f weight-bearing most important

Pectoral: a, c, d Pelvic: b, e, f

10. Distinguish between the true pelvis and the false pelvis

True pelvis :The space inferior to the pelvic False pelvis: The space between the iliac crest.

11. Match the terms in the key with the appropriate leader lines on the photograph of the lateral view of the hip bone.

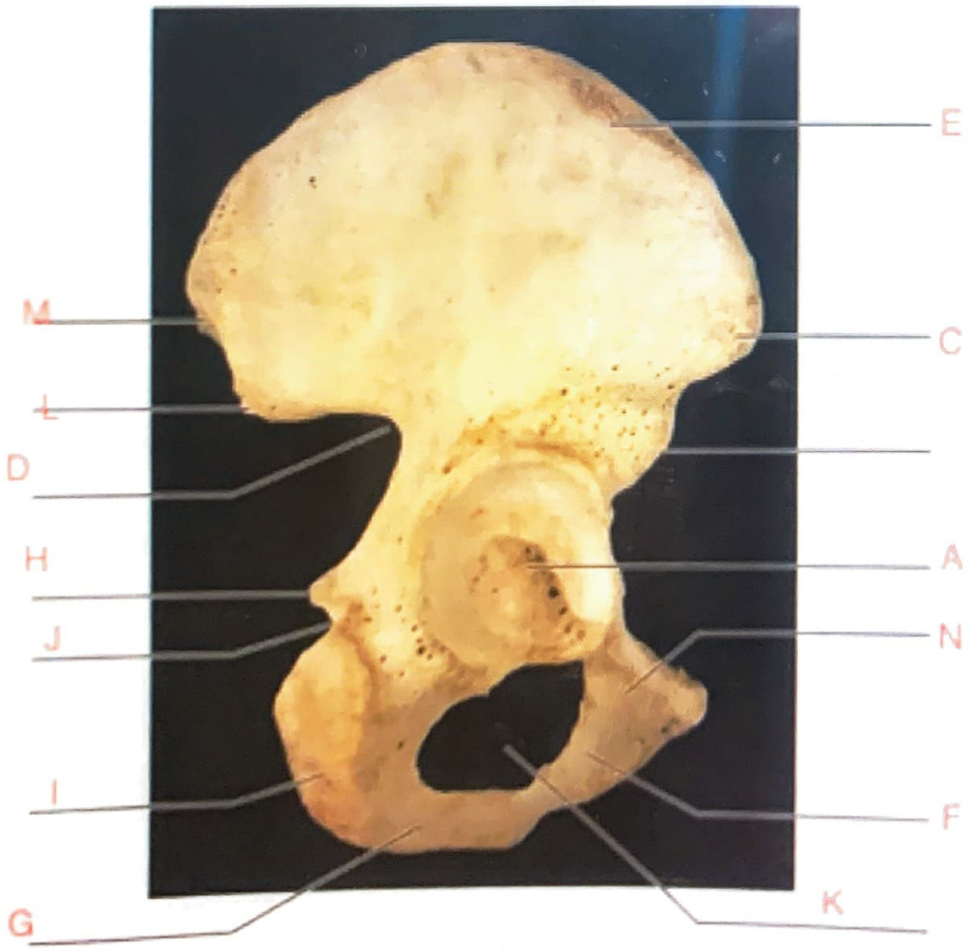

Key:
a acetabulum
b anterior inferior iliac spine
c anterior superior iliac spine
d greater sciatic notch
e iliac crest
f inferior pubic ramus
g ischial ramus
h ischial spine
i ischial tuberosity
j lesser sciatic notch
k obturator foramen
l posterior inferior iliac spine
m posterior superior iliac spine
n superior pubic ramus

12. Match the bone names and markings in column B with the descriptions in column A. The items in column B may be used more than once.

Column A

(I) Ilium _____ (K) Ischium _____ and

(S) Pubis _____ 1. fuse to form the hip bone

(J) Ischial tuberosity _____ 2. rough projection that supports body weight when sitting

(R) Pubic symphysis _____ 3. point where the hip bones join anteriorly

(H) Iliac crest _____ 4. superiormost margin of the hip bone

(A) acetabulum _____ 5. deep socket in the hip bone that receives the head of the thigh bone

(T) Sacroiliac joint _____ 6. joint between axial skeleton and pelvic girdle

(C) Femur _____ 7. longest, strongest bone in body

(G) (D) Fibula _____ 8. thin, lateral leg bone

(M) Greater Sciatic notch _____ 9. permits passage of the sciatic nerve

(X) Tibial Tuberosity lesser Sciatic notch _____ 10. notch located inferior to the ischial spine

(Q) Patella _____ 11. point where the patellar ligament attaches

(W) Tibia _____ 12. kneecap

(N) medial malleolus _____ 13. shinbone

(L) lateral malleolus _____ 14. medial ankle projection

(B) Calcaneus _____ 15. lateral ankle projection

(V) Tarsals _____ 16. largest tarsal bone

(O) metatarsals _____ 17. ankle bones

(P) obturator foramen _____ 18. bones forming the instep of the foot

(E) Tuberosity _____ and (F) Greater & lesser Trochanters _____ 19. opening in hip bone formed by the pubic and ischial rami

(U) Talus _____ 20. sites of muscle attachment on the proximal femur

(U) Talus _____ 21. tarsal bone that "sits" on the calcaneus

(W) Tibia _____ 22. weight-bearing bone of the leg

(U) Talus _____ 23. tarsal bone that articulates with the tibia

Column B

a. acetabulum
b. calcaneus
c. femur
d. fibula
e. gluteal tuberosity
f. greater and lesser trochanters
g. greater sciatic notch
h. iliac crest
i. ilium
j. ischial tuberosity
k. ischium
l. lateral malleolus
m. lesser sciatic notch
n. medial malleolus
o. metatarsals
p. obturator foramen
q. patella
r. pubic symphysis
s. pubis
t. sacroiliac joint
u. talus
v. tarsals
w. tibia
x. tibial tuberosity

15. Match the terms in the key with the appropriate leader lines on the photograph of the posterior view of the articulated tibia and fibula.

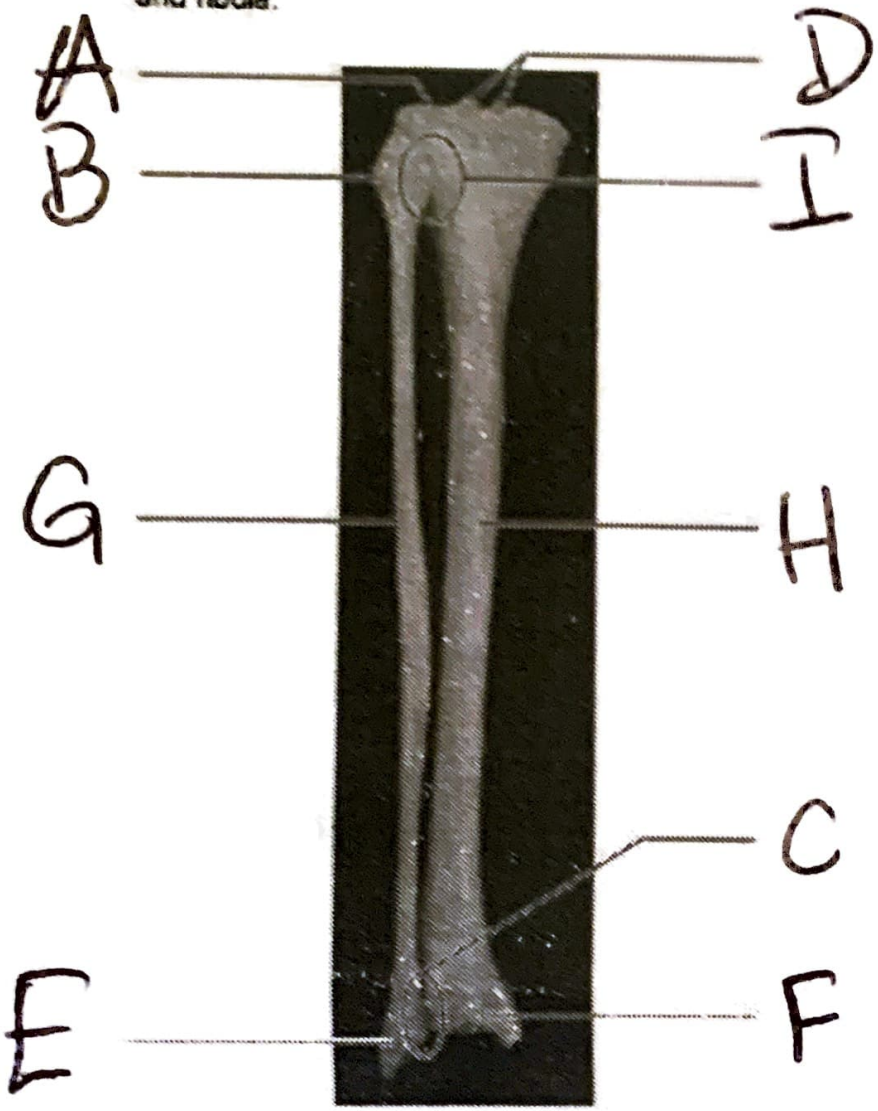

Key:

a. articular surface of the lateral condyle

b. head of the fibula

c. inferior tibiofibular joint

d. intercondylar eminence

e. lateral malleolus

f. medial malleolus

g. shaft of the fibula

h. shaft of the tibia

i. superior tibiofibular joint

16. Are the bones of the leg shown above from the left or from the right leg? Left

Explain how you can tell which side of the body they are from. I can tell because the fibulle's shart is on the right side.

17. Match the terms in the key with the appropriate leader lines on the photograph of the superior view of the articulated foot.

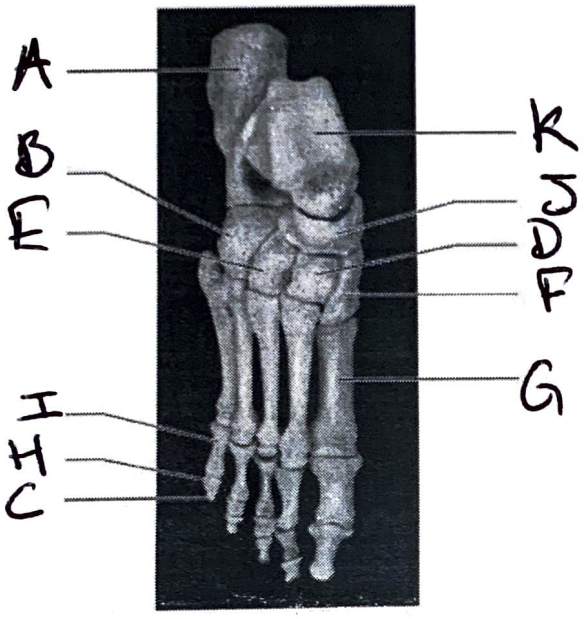

Key:

a. calcaneus

b. cuboid

c. distal phalanx

d. intermediate cuneiform

e. lateral cuneiform

f. medial cuneiform

g. metatarsal

h. middle phalanx

i. navicular

j. proximal phalanx

k. talus

18. FOOSH is an acronym that stands for **Fall on Outstretched Hand**. Discuss possible fractures and dislocations that might occur with an injury of this type.

A Coles fracture and a Scaphoid fracture.

19. Describe some of the features of the female pelvis that provide for compatibility with vaginal birth. The Pelvis in the female is wider and it's more flexible for child birth.

20. Your X-ray exam reveals that you have fractured your fibula. Your physician remarks, "Well, it's better than breaking your tibia." Explain why a fracture of the tibia would be worse than a fracture of the fibula. The tibia is more stronger It holds up the body weight.