



Instructors may assign a portion of the Review Sheet questions using Mastering A&P™

10 EXERCISE

REVIEW SHEET

The Appendicular Skeleton

Name Shanice Hendricks Lab Time/Date _____

Bones of the Pectoral Girdle and Upper Limb

1. Fill in the blank to complete the statements below:

- a. The bones that form the pectoral girdle are the Clavicle and Scapula.
- b. The upper limb is formed by the arm bone, the humerus, and the two bones of the forearm, the radius and ulna.
- c. The carpals are the wrist bones. List the proximal row of wrist bones from lateral to medial: _____
Scaphoid, Lunate, Triquetrum, Pisiform

List the distal row of wrist bones from lateral to medial: _____

- d. The metacarpals form the palm of the hand, and the heads of these bones form the knuckles.
- e. A single finger bone is called a phalanx. Each hand has 3 finger bones, called phalanges.

2. Match the bone markings in column B with the descriptions in column A.

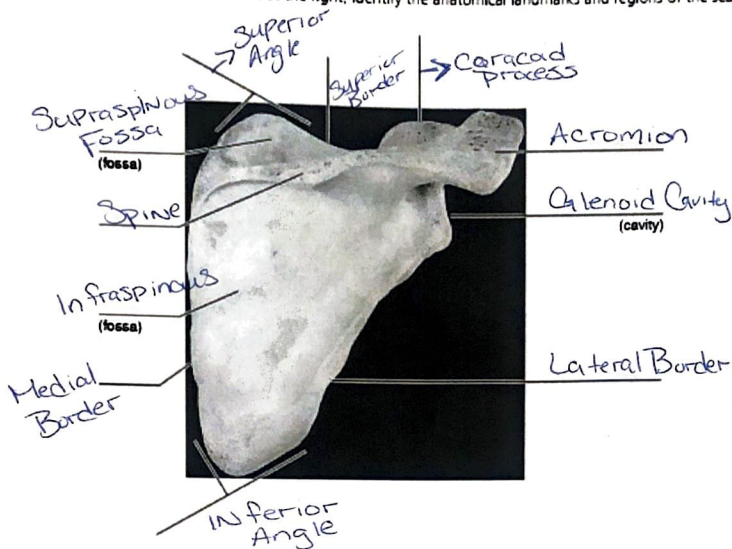
Column A

- F 1. depression in the scapula that articulates with the humerus
- K 2. surface on the radius that receives the head of the ulna
- B 3. lateral rounded knob on the distal humerus
- H 4. posterior depression on the distal humerus
- E 5. a roughened area on the lateral humerus: deltoid attachment site
- C 6. hooklike process; biceps brachii attachment site
- I 7. surface on the ulna that receives the head of the radius
- G 8. medial condyle of the humerus that articulates with the ulna
- A 9. lateral end of the spine of the scapula; clavicle articulation site
- J 10. small bump on the humerus, often called the "funny bone"
- D 11. anterior depression, superior to the trochlea, that receives part of the ulna when bending at the elbow

Column B

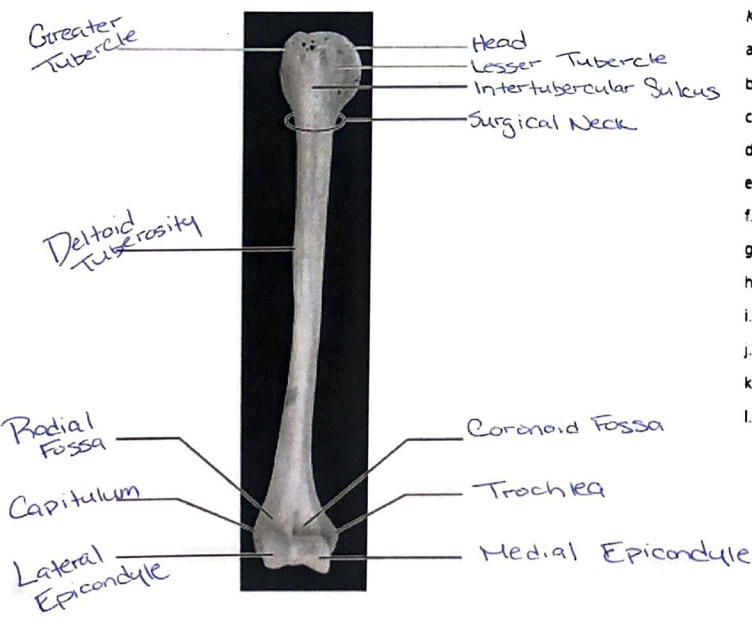
- a. acromion
- b. capitulum
- c. coracoid process
- d. coronoid fossa
- e. deltoid tuberosity
- f. glenoid cavity
- g. medial epicondyle
- h. olecranon fossa
- i. radial notch
- j. trochlea
- k. ulnar notch

3. Using items from the list at the right, identify the anatomical landmarks and regions of the scapula.



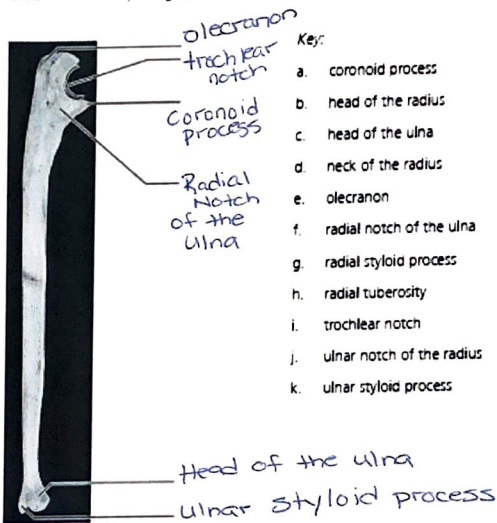
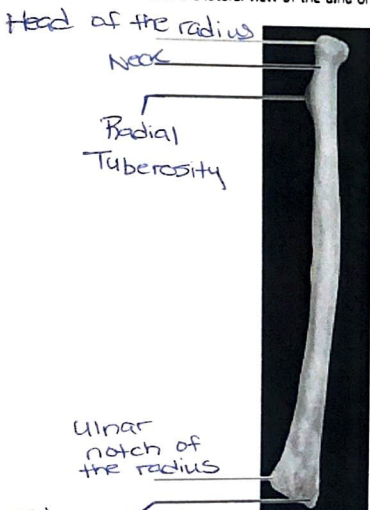
- Key:
- a. acromion
 - b. coracoid process
 - c. glenoid cavity
 - d. inferior angle
 - e. infraspinous fossa
 - f. lateral border
 - g. medial border
 - h. spine
 - i. superior angle
 - j. superior border
 - k. supraspinous fossa

4. Match the terms in the key with the appropriate leader lines on the photograph of the humerus.



- Key:
- a. capitulum
 - b. coronoid fossa
 - c. deltoid tuberosity
 - d. greater tubercle
 - e. head
 - f. intertubercular sulcus
 - g. lateral epicondyle
 - h. lesser tubercle
 - i. medial epicondyle
 - j. radial fossa
 - k. surgical neck
 - l. trochlea

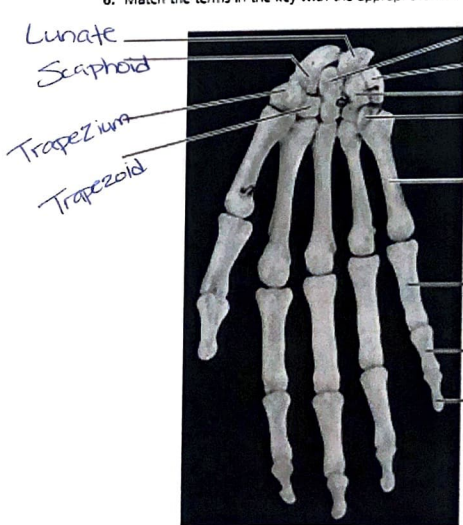
5. Match the terms in the key with the appropriate leader lines on the photographs of the posterior view of the radius on the left and the lateral view of the ulna on the right.



Key:

- a. coronoid process
- b. head of the radius
- c. head of the ulna
- d. neck of the radius
- e. olecranon
- f. radial notch of the ulna
- g. radial styloid process
- h. radial tuberosity
- i. trochlear notch
- j. ulnar notch of the radius
- k. ulnar styloid process

6. Match the terms in the key with the appropriate leader lines on the photograph of the anterior view of the hand.



Key:

- a. capitate
- b. distal phalanx
- c. hamate
- d. lunate
- e. metacarpal
- f. middle phalanx
- g. pisiform
- h. proximal phalanx
- i. scaphoid
- j. trapezium
- k. trapezoid
- l. triquetrum

7. Name the two bone markings that form the proximal radioulnar joint.

Ulnar radial notch & Annular Ligament

8. Name the two bone markings that form the distal radioulnar joint.

Ulnar notch & Radius

Bones of the Pelvic Girdle and Lower Limb

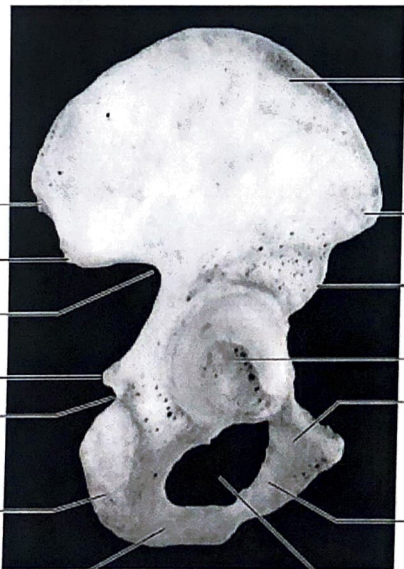9. Compare the pectoral and pelvic girdles by choosing appropriate descriptive terms from the key.

- Key:
- | | |
|-------------------------------|--|
| a. flexibility most important | d. insecure axial and limb attachments |
| b. massive | e. secure axial and limb attachments |
| c. lightweight | f. weight-bearing most important |

Pectoral: B E F Pelvic: A D C

10. Distinguish between the true pelvis and the false pelvis. True Pelvis is the region inferior to the pelvic brim which is encircled by bone. False Pelvis is the area medial to the flaring iliac bones

11. Match the terms in the key with the appropriate leader lines on the photograph of the lateral view of the hip bone.



Key:

- a. acetabulum
- b. anterior inferior iliac spine
- c. anterior superior iliac spine
- d. greater sciatic notch
- e. iliac crest
- f. inferior pubic ramus
- g. ischial ramus
- h. ischial spine
- i. ischial tuberosity
- j. lesser sciatic notch
- k. obturator foramen
- l. posterior inferior iliac spine
- m. posterior superior iliac spine
- n. superior pubic ramus

12. Match the bone names and markings in column B with the descriptions in column A. The items in column B may be used more than once.

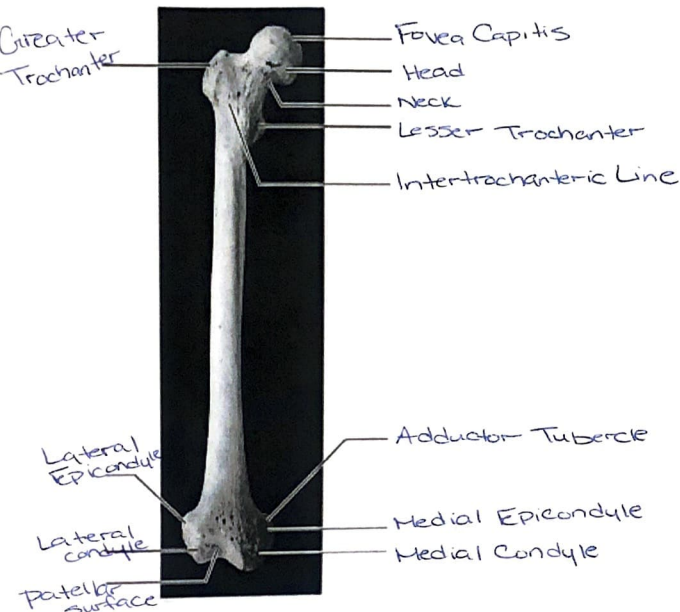
Column A

- I _____, K _____, and
S _____ 1. fuse to form the hip bone
K _____ 2. rough projection that supports body weight when sitting
R _____ 3. point where the hip bones join anteriorly
H _____ 4. superiormost margin of the hip bone
A _____ 5. deep socket in the hip bone that receives the head of the thigh bone
T _____ 6. joint between axial skeleton and pelvic girdle
C _____ 7. longest, strongest bone in body
D _____ 8. thin, lateral leg bone
G _____ 9. permits passage of the sciatic nerve
M _____ 10. notch located inferior to the ischial spine
X _____ 11. point where the patellar ligament attaches
Q _____ 12. kneecap
W _____ 13. shinbone
N _____ 14. medial ankle projection
L _____ 15. lateral ankle projection
B _____ 16. largest tarsal bone
V _____ 17. ankle bones
O _____ 18. bones forming the instep of the foot
P _____ 19. opening in hip bone formed by the pubic and ischial rami
E _____ and F _____ 20. sites of muscle attachment on the proximal femur
U _____ 21. tarsal bone that "sits" on the calcaneus
W _____ 22. weight-bearing bone of the leg
U _____ 23. tarsal bone that articulates with the tibia

Column B

- a. acetabulum
 b. calcaneus
 c. femur
 d. fibula
 e. gluteal tuberosity
 f. greater and lesser trochanters
 g. greater sciatic notch
 h. iliac crest
 i. ilium
 j. ischial tuberosity
 k. ischium
 l. lateral malleolus
 m. lesser sciatic notch
 n. medial malleolus
 o. metatarsals
 p. obturator foramen
 q. patella
 r. pubic symphysis
 s. pubis
 t. sacroiliac joint
 u. talus
 v. tarsals
 w. tibia
 x. tibial tuberosity

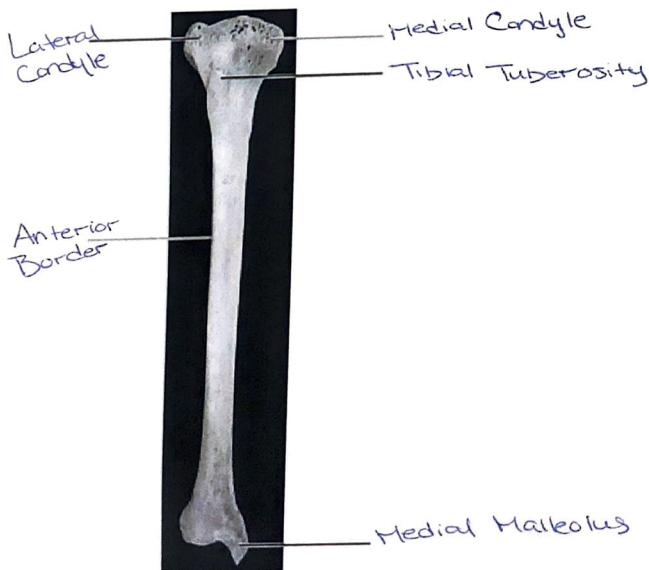
13. Match the terms in the key with the appropriate leader lines on the photograph of the anterior view of the femur.



Key:

- a. adductor tuberde
- b. fovea capitis
- c. greater trochanter
- d. head
- e. intertrochanteric line
- f. lateral condyle
- g. lateral epicondyle
- h. lesser trochanter
- i. medial condyle
- j. medial epicondyle
- k. neck
- l. patellar surface

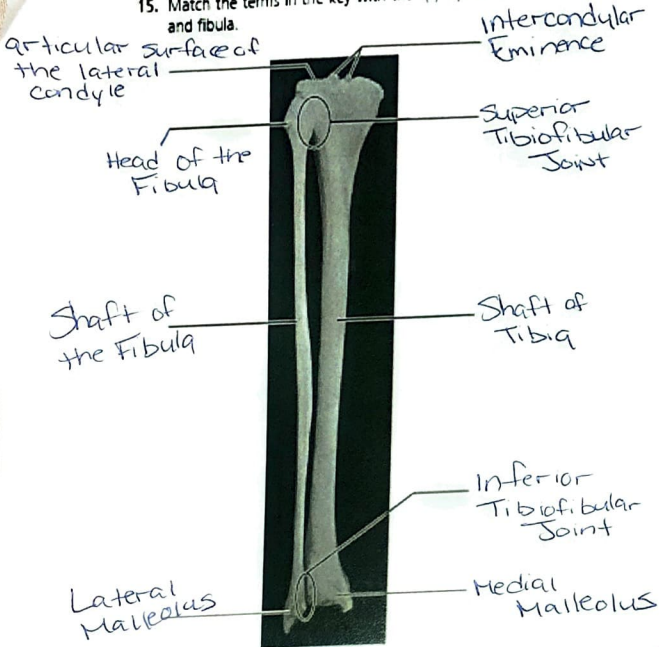
14. Match the terms in the key with the appropriate leader lines on the photograph of the anterior view of the tibia.



Key:

- a. anterior border
- b. lateral condyle
- c. medial condyle
- d. medial malleolus
- e. tibial tuberosity

15. Match the terms in the key with the appropriate leader lines on the photograph of the posterior view of the articulated tibia and fibula.



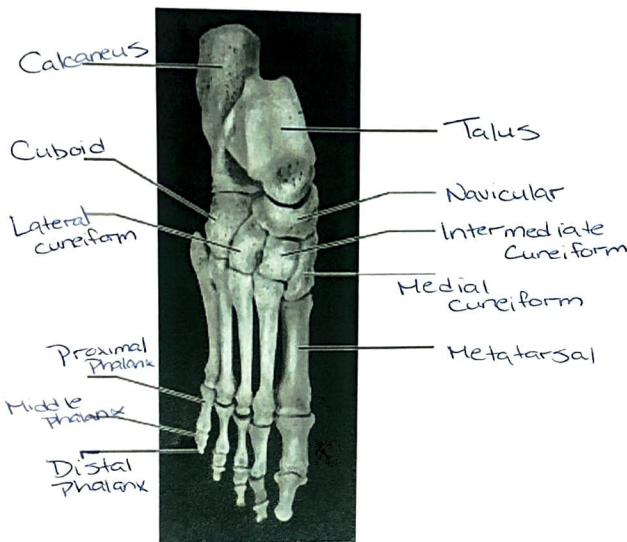
Key:

- a. articular surface of the lateral condyle
- b. head of the fibula
- c. inferior tibiofibular joint
- d. intercondylar eminence
- e. lateral malleolus
- f. medial malleolus
- g. shaft of the fibula
- h. shaft of the tibia
- i. superior tibiofibular joint

16. Are the bones of the leg shown above from the left or from the right leg? Right Leg

Explain how you can tell which side of the body they are from. Posterior image, Fibula is lateral bone and facing outside of leg.

17. Match the terms in the key with the appropriate leader lines on the photograph of the superior view of the articulated foot.



Key:

- a. calcaneus
- b. cuboid
- c. distal phalanx
- d. intermediate cuneiform
- e. lateral cuneiform
- f. medial cuneiform
- g. metatarsal
- h. middle phalanx
- i. navicular
- j. proximal phalanx
- k. talus

18. FOOSH is an acronym that stands for Fall on Outstretched Hand. Discuss possible fractures and dislocations that might occur with an injury of this type.

Breaking the hamate carpal bones of the wrist are most likely. Dislocations are common.

19. Describe some of the features of the female pelvis that provide for compatibility with vaginal birth.

Cavity of the pelvis has greater capacity to allow passage of a child through the pelvic outlet.

20. Your X-ray exam reveals that you have fractured your fibula. Your physician remarks, "Well, it's better than breaking your tibia." Explain why a fracture of the tibia would be worse than a fracture of the fibula.

Fibula provides lateral support and stability for the tibia but does not bear weight like the tibia does.