

1

10 questions
10 points

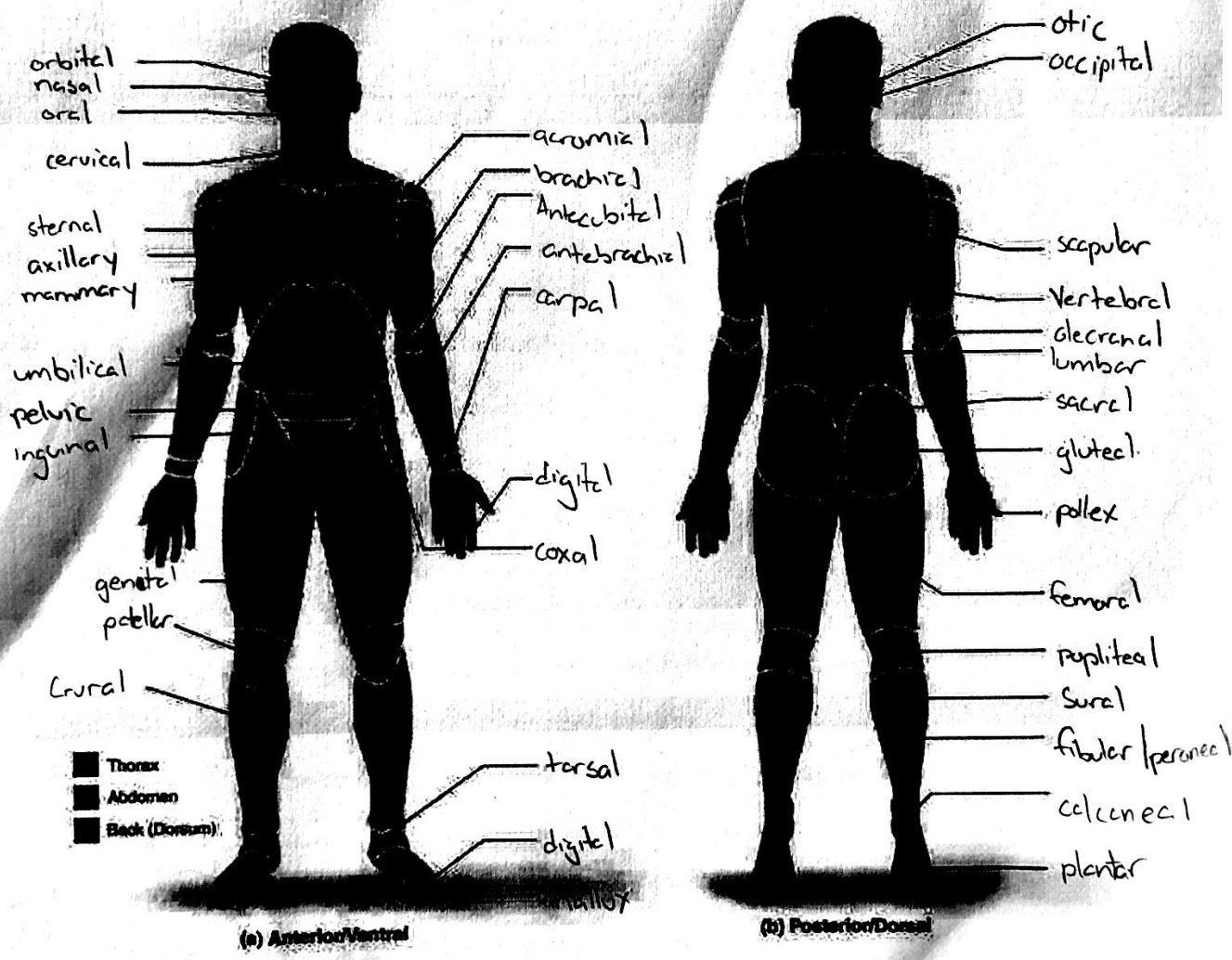
Language of Anatomy

Name Brian Chen

Lab Time/Date _____

Regional Terms

- Describe completely the standard human anatomical position. body erect, feet apart, arms to the side, palms and toes forward
- Use the regional terms to correctly label the body regions indicated on the figures below.



Directional Terms, Planes, and Sections

3. Define plane: a surface that makes a section through the body

4. Several incomplete statements appear below. Correctly complete each statement by choosing the appropriate anatomical term from the choices. Use each term only once.

anterior	inferior	posterior	superior
distal	lateral	proximal	transverse
frontal	medial	sagittal	

- The thoracic cavity is superior to the abdominopelvic cavity.
 - The trachea (windpipe) is anterior to the vertebral column.
 - The wrist is proximal to the hand.
 - If an incision cuts the heart into left and right parts, a sagittal plane of section was used.
 - The nose is medial to the cheekbones.
 - The thumb is lateral to the ring finger.
 - The vertebral cavity is inferior to the cranial cavity.
 - The knee is distal to the thigh.
 - The plane that separates the head from the neck is the transverse plane.
 - The popliteal region is posterior to the patellar region.
 - The plane that separates the anterior body surface from the posterior body surface is the frontal plane.
5. Correctly identify each of the body planes by writing the appropriate term on the answer line below the drawing.



(a) frontal



(b) sagittal



(c) transverse

Body Cavities

- Name the muscle that subdivides the ventral body cavity. diaphragm
- Which body cavity provides the least protection to its internal structures? abdominal
- For the body cavities listed, name one organ located in each cavity.
 - cranial cavity brain
 - vertebral cavity spinal cord