

Name Mia Genovaes

Lab Time/Date _____

EXERCISE

1

REVIEW SHEET

The Language of Anatomy

Surface Anatomy

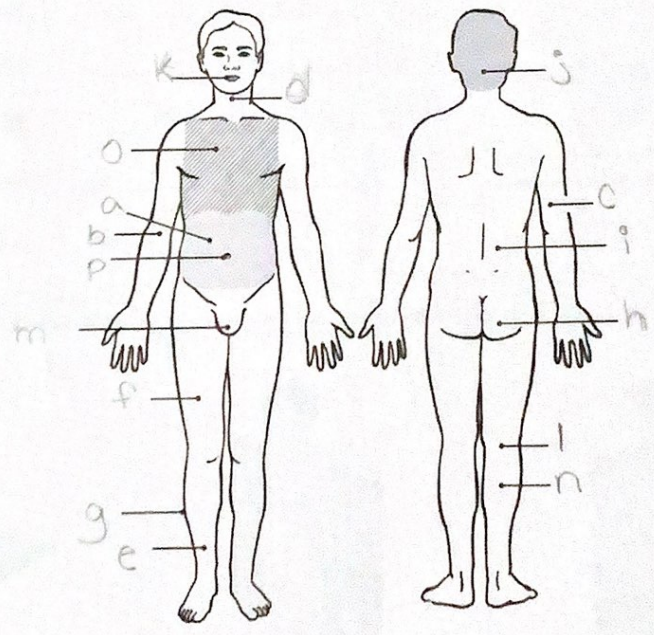
1. Match each of the numbered descriptions with the related term in the key, and record the key letter or term in front of the description.

- Key:
- | | | |
|--------------|-------------|-------------|
| a. buccal | c. cephalic | e. patellar |
| b. calcaneal | d. digital | f. scapular |

- | | | | |
|----------------|--------------------------|----------------|----------------------------|
| <u>a</u> _____ | 1. cheek | <u>e</u> _____ | 4. anterior aspect of knee |
| <u>d</u> _____ | 2. fingers | <u>b</u> _____ | 5. heel of foot |
| <u>f</u> _____ | 3. shoulder blade region | <u>c</u> _____ | 6. head |

2. Indicate the following body areas on the accompanying diagram by placing the correct key letter at the end of each line.

- Key:
- a. abdominal
 - b. antecubital
 - c. brachial
 - d. cervical
 - e. crural
 - f. femoral
 - g. fibular
 - h. gluteal
 - i. lumbar
 - j. occipital
 - k. oral
 - l. popliteal
 - m. pubic
 - n. sural
 - o. thoracic
 - p. umbilical



3. Classify each of the terms in the key of question 2 above into one of the large body regions indicated below. Insert the appropriate key letters on the answer blanks.

- | | | | |
|--------------------------------|-----------------|--|----------|
| <u>kg, a, f, i, n, c</u> _____ | 1. appendicular | <u>k, d, j, o, a, e, h, i, m</u> _____ | 2. axial |
|--------------------------------|-----------------|--|----------|

Body Orientation, Direction, Planes, and Sections

4. Describe completely the standard human anatomical position. Standing upright with palms facing forward.

5. Define *section*. A cut along an imaginary plane through the body wall or organ.
6. Several incomplete statements are listed below. Correctly complete each statement by choosing the appropriate anatomical term from the key. Record the key letters and/or terms on the correspondingly numbered blanks below. Some terms are used more than once.

Key: a. anterior d. inferior g. posterior j. superior
 b. distal e. lateral h. proximal k. transverse
 c. frontal f. medial i. sagittal

In the anatomical position, the face and palms are on the 1 body surface; the buttocks and shoulder blades are on the 2 body surface; and the top of the head is the most 3 part of the body. The ears are 4 and 5 to the shoulders and 6 to the nose. The heart is 7 to the vertebral column (spine) and 8 to the lungs. The elbow is 9 to the fingers but 10 to the shoulder. The abdominopelvic cavity is 11 to the thoracic cavity and 12 to the spinal cavity. In humans, the dorsal surface can also be called the 13 surface; however, in quadruped animals, the dorsal surface is the 14 surface.

If an incision cuts the heart into right and left parts, the section is a 15 section; but if the heart is cut so that superior and inferior portions result, the section is a 16 section. You are told to cut a dissection animal along two planes so that both kidneys are observable in each section. The two sections that will always meet this requirement are the 17 and 18 sections. A section that demonstrates the continuity between the spinal and cranial cavities is a 19 section.

- | | | |
|-------------|--------------|--------------|
| 1. <u>a</u> | 8. <u>f</u> | 14. <u>j</u> |
| 2. <u>g</u> | 9. <u>h</u> | 15. <u>i</u> |
| 3. <u>j</u> | 10. <u>b</u> | 16. <u>k</u> |
| 4. <u>f</u> | 11. <u>d</u> | 17. <u>i</u> |
| 5. <u>j</u> | 12. <u>a</u> | 18. <u>k</u> |
| 6. <u>e</u> | 13. <u>g</u> | 19. <u>i</u> |
| 7. <u>a</u> | | |

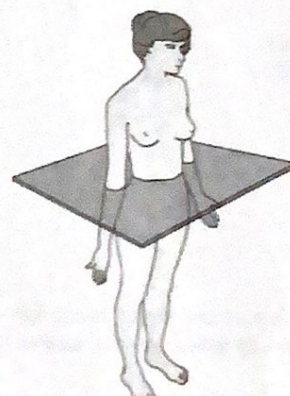
7. Correctly identify each of the body planes by inserting the appropriate term for each on the answer line below the drawing.



(a) Median

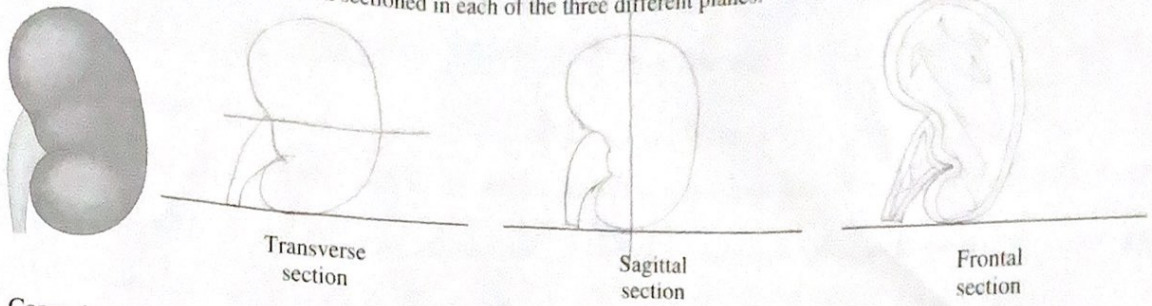


(b) Frontal



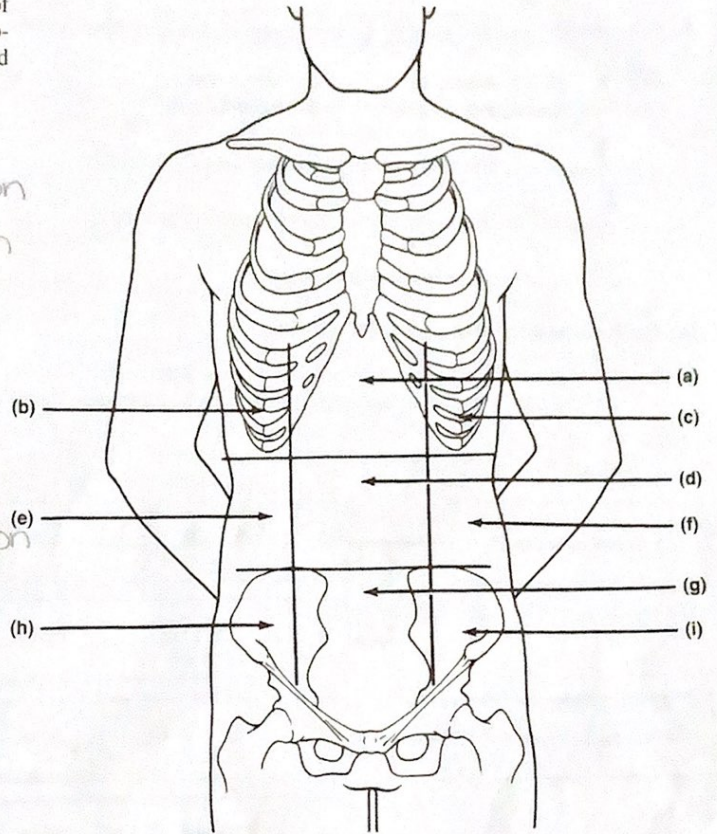
(c) Transverse

8. Draw a kidney as it appears when sectioned in each of the three different planes.



9. Correctly identify each of the nine regions of the abdominopelvic cavity by inserting the appropriate term for each of the letters indicated in the drawing.

- a. Epigastric region
- b. Right hypochondriac region
- c. Left hypochondriac region
- d. Umbilical region
- e. Right lumbar region
- f. Left lumbar region
- g. Hypogastric (pubic) region
- h. Right iliac (inguinal) region
- i. Left iliac (inguinal) region



Body Cavities

10. Which body cavity would have to be opened for the following types of surgery or procedures? (Insert letter of key choice in same-numbered blank. More than one choice may apply.)

- Key: a. abdominopelvic c. dorsal e. thoracic
 b. cranial d. spinal f. ventral

- e/f 1. surgery to remove a cancerous lung lobe a/f 4. appendectomy
- f/a 2. removal of the uterus, or womb a/f 5. stomach ulcer operation
- b/c 3. removal of a brain tumor d/c 6. delivery of pre-operative "saddle" anesthesia

11. Name the muscle that subdivides the ventral body cavity. The diaphragm

12. What are the bony landmarks of the abdominopelvic cavity? The pelvic bones and spine.

13. Which body cavity affords the least protection to its internal structures? The ventral cavity.

14. What is the function of the serous membranes of the body? Produces a fluid that allows visceral organs to slide/rub against the body with minimal friction.

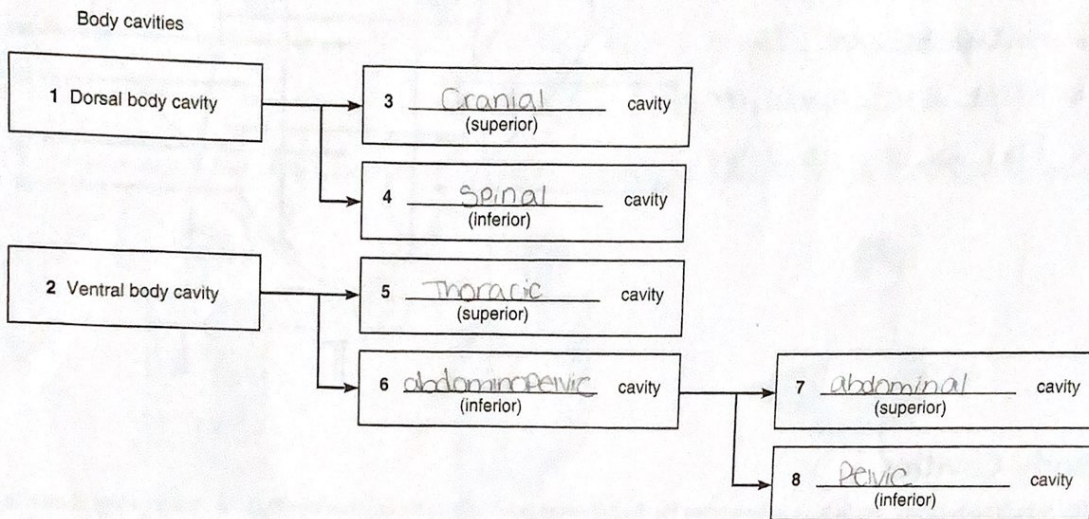
15. Using the key choices, identify the small body cavities described below.

- Key: a. middle ear cavity c. oral cavity e. synovial cavity
 b. nasal cavity d. orbital cavity

- d 1. holds the eyes in an anterior-facing position c 4. contains the tongue
a 2. houses three tiny bones involved in hearing e 5. surrounds a joint
b 3. contained within the nose

16. On the incomplete flowchart provided below:

- Fill in the cavity names as appropriate to boxes 3–8.
- Then, using either the name of the cavity or the box numbers, identify the descriptions in the list that follows.



- 1 a. contained within the skull and vertebral column 5 e. contains the heart
8 b. houses female reproductive organs 6 f. contains the small intestine
4 c. the most protective body cavity 5 g. bounded by the ribs
7 d. its name means belly 7 h. its walls are muscular

Name Mia Genoves

Lab Time/Date _____

EXERCISE 2

Organ Systems Overview

REVIEW SHEET

1. Use the key below to indicate the body systems that perform the following functions for the body; note that some body systems are used more than once. Then, circle the organ systems (in the key) that are present in all subdivisions of the ventral body cavity.

- Key: a. cardiovascular d. integumentary g. nervous j. skeletal
b. digestive e. lymphatic/immunity h. reproductive k. urinary
c. endocrine f. muscular i. respiratory

- k _____ 1. rids the body of nitrogen-containing wastes
- c _____ 2. is affected by removal of the thyroid gland
- j _____ 3. provides support and levers on which the muscular system acts
- a _____ 4. includes the heart
- h _____ 5. has a menstrual cycle in females
- e _____ 6. protects underlying organs from drying out and from mechanical damage
- d _____ 7. protects the body; destroys bacteria and tumor cells
- b _____ 8. breaks down ingested food into its building blocks
- i _____ 9. removes carbon dioxide from the blood
- a _____ 10. delivers oxygen and nutrients to the tissues
- f _____ 11. moves the limbs; facilitates facial expression
- k _____ 12. conserves body water or eliminates excesses
- h _____ and c _____ 13. facilitate conception and childbearing
- c _____ 14. controls the body by means of chemical molecules called hormones
- d _____ 15. is damaged when you cut your finger or get a severe sunburn

2. Using the above key, choose the *organ system* to which each of the following sets of organs or body structures belongs.

- e _____ 1. thymus, spleen, lymphatic vessels d _____ 5. epidermis, dermis, and cutaneous sense organs
- j _____ 2. bones, cartilages, tendons h _____ 6. testis, ductus deferens, urethra
- c _____ 3. pancreas, pituitary, adrenals b _____ 7. esophagus, large intestine, rectum
- i _____ 4. trachea, bronchi, lungs f _____ 8. muscles of the thigh, postural muscles

3. Using the key below, place the following organs in their proper body cavity.

- Key: a. abdominopelvic b. cranial c. spinal d. thoracic
- | | | |
|-----------------------------|-----------------------------|---------------------|
| <u>a</u> 1. stomach | <u>a</u> 4. liver | <u>d</u> 7. heart |
| <u>d</u> 2. esophagus | <u>c</u> 5. spinal cord | <u>d</u> 8. trachea |
| <u>a</u> 3. large intestine | <u>a</u> 6. urinary bladder | <u>a</u> 9. rectum |

4. Using the organs listed in question 3 above, record, by number, which would be found in the abdominal regions listed below.

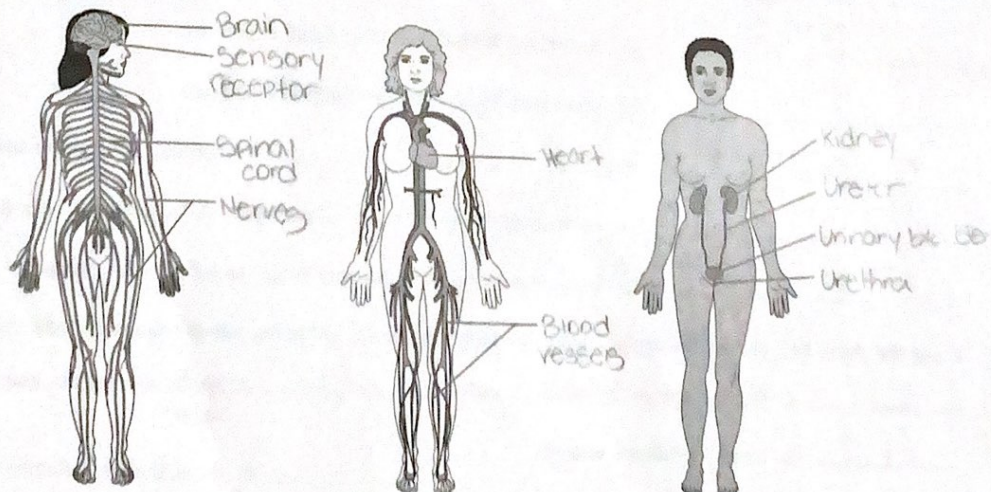
- | | |
|--------------------------------------|---|
| <u>3, 6, 9</u> 1. hypogastric region | <u>1, 3, 4</u> 4. epigastric region |
| <u>3</u> 2. right lumbar region | <u>3</u> 5. left iliac region |
| <u>3</u> 3. umbilical region | <u>1, 3, 4</u> 6. left hypochondriac region |

5. The levels of organization of a living body are chemical, cell, tissue, organ, organ system, and organism.

6. Define organ. A structure composed of two or more tissue types that performs a specific function for the body.

7. Using the terms provided, correctly identify all of the body organs provided with leader lines in the drawings shown below. Then name the organ systems by entering the name of each on the answer blank below each drawing.

- Key: blood vessels heart nerves spinal cord urethra
 brain kidney sensory receptor ureter urinary bladder



- a. Nervous system b. Circulatory system c. Excretory system

8. Why is it helpful to study the external and internal structures of the rat? The internal and external structure of the rat is similar to the structure and function of the human body.