

NAME Cherrina Campbell

LAB TIME/DATE \_\_\_\_\_

REVIEW SHEET  
EXERCISE 1

# The Language of Anatomy

## Surface Anatomy

1. Match each of the following descriptions with a key equivalent, and record the key letter or term in front of the description.

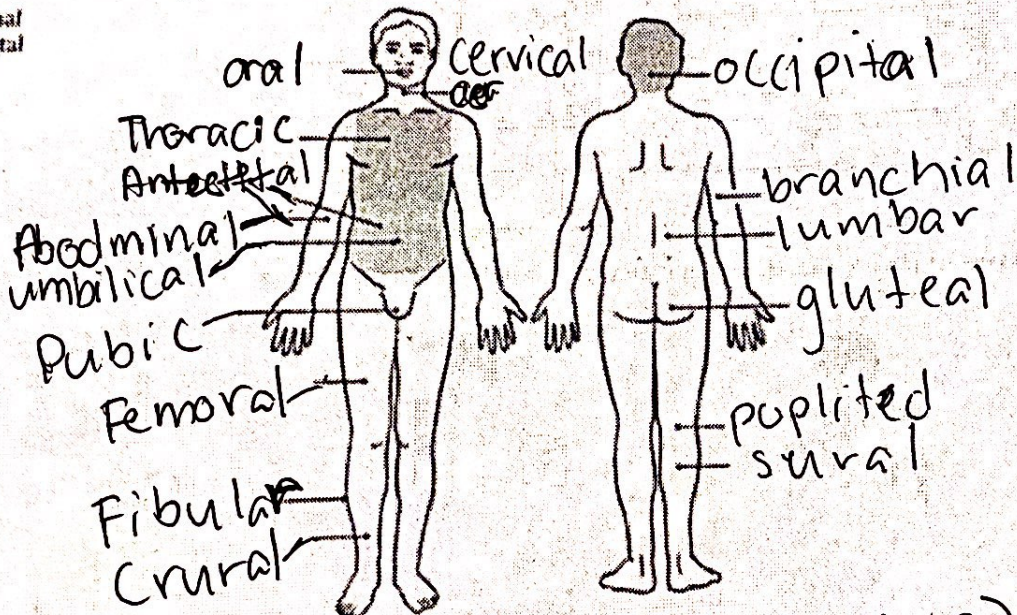
Key: a. buccal                      c. cephalic                      e. patellar  
b. calcaneal                      d. digital                      f. scapular

- |                |                              |                |                            |
|----------------|------------------------------|----------------|----------------------------|
| <u>a</u> _____ | 1. cheek                     | <u>e</u> _____ | 4. anterior aspect of knee |
| <u>d</u> _____ | 2. pertaining to the fingers | <u>b</u> _____ | 5. heel of foot            |
| <u>f</u> _____ | 3. shoulder blade region     | <u>c</u> _____ | 6. pertaining to the head  |

2. Indicate the following body areas on the accompanying diagram by placing the correct key letter at the end of each line.

Key:

- a. abdominal
- b. antecubital
- c. brachial
- d. cervical
- e. crural
- f. femoral
- g. fibular
- h. gluteal
- i. lumbar
- j. occipital
- k. oral
- l. popliteal
- m. pubic
- n. sural
- o. thoracic
- p. umbilical



Anterior (A)      Posterior (B)

3. Classify each of the terms in the key of question 2 above into one of the large body regions indicated below. Insert the appropriate key letters on the answer blanks.

B F E \_\_\_\_\_ 1. appendicular      J, O, A, P, M, D \_\_\_\_\_ axial

## Body Orientation, Direction, Planes, and Sections

4. Describe completely the standard human anatomical position. The standard anatomical position is with the body standing up straight facing forward, with arms by the side of the body and palms facing forward.

5. Define section. ACUT that is made around the body plane

6. Several incomplete statements are listed below. Correctly complete each statement by choosing the appropriate anatomical term from the key. Record the key letters and/or terms on the correspondingly numbered blanks below.

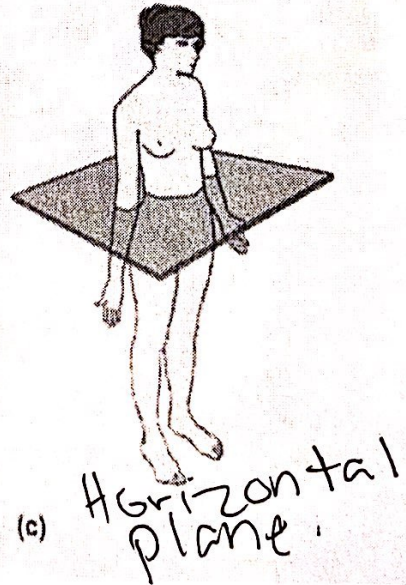
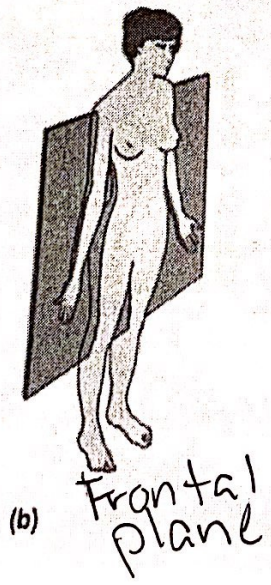
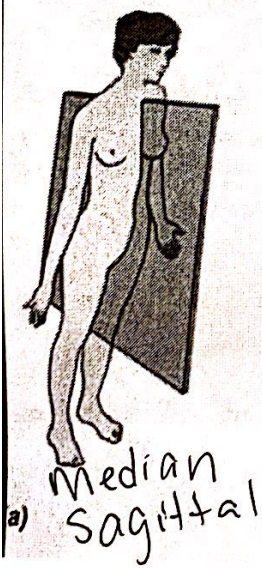
- Key: a. anterior      d. inferior      g. posterior      j. superior  
 b. distal          e. lateral      h. proximal      k. transverse  
 c. frontal          f. medial      i. sagittal

In the anatomical position, the face and palms are on the 1 body surface; the buttocks and shoulder blades are on the 2 body surface; and the top of the head is the most 3 part of the body. The ears are 4 and 5 to the shoulders and 6 to the nose. The heart is 7 to the vertebral column (spine) and 8 to the lungs. The elbow is 9 to the fingers but 10 to the shoulder. The abdominopelvic cavity is 11 to the thoracic cavity and 12 to the spinal cavity. In humans, the dorsal surface can also be called the 13 surface; however, in quadruped animals, the dorsal surface is the 14 surface.

If an incision cuts the heart into right and left parts, the section is a 15 section; but if the heart is cut so that superior and inferior portions result, the section is a 16 section. You are told to cut a dissection animal along two planes so that both kidneys are observable in each section. The two sections that will always meet this requirement are the 17 and 18 sections. A section that demonstrates the continuity between the spinal and cranial cavities is a 19 section.

- |                     |                      |                       |
|---------------------|----------------------|-----------------------|
| 1. <u>Anterior</u>  | 8. <u>Medial</u>     | 14. <u>Superior</u>   |
| 2. <u>Posterior</u> | 9. <u>Proximal</u>   | 15. <u>sagittal</u>   |
| 3. <u>Superior</u>  | 10. <u>Distal</u>    | 16. <u>Transverse</u> |
| 4. <u>Medial</u>    | 11. <u>inferior</u>  | 17. <u>Frontal</u>    |
| 5. <u>Superior</u>  | 12. <u>Anterior</u>  | 18. <u>Transverse</u> |
| 6. <u>lateral</u>   | 13. <u>Posterior</u> | 19. <u>sagittal</u>   |
| 7. <u>Anterior</u>  |                      |                       |

Correctly identify each of the body planes by inserting the appropriate term for each on the answer line below the drawing



8. Draw a kidney as it appears when sectioned in each of the three different planes.



Transverse section



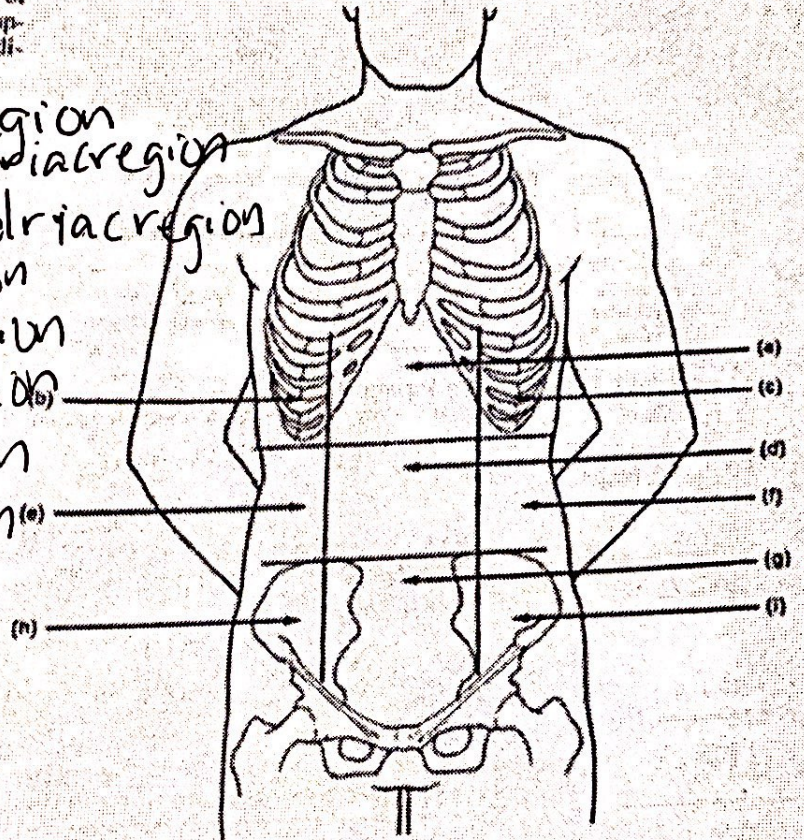
Sagittal section



Frontal section

9. Correctly identify each of the nine areas of the abdominal surface by inserting the appropriate term for each of the letters indicated in the drawing.

- a. Epigastric region
- b. Right hypochondriac region
- c. Left hypochondriac region
- d. umbilical region
- e. Right lumbar region
- f. Left lumbar region
- g. hypogastric region
- h. Right iliac region
- i. left iliac region



### Body Cavities

10. Which body cavity would have to be opened for the following types of surgery or procedures? (Insert letter of key choice in same-numbered blank. More than one choice may apply.)

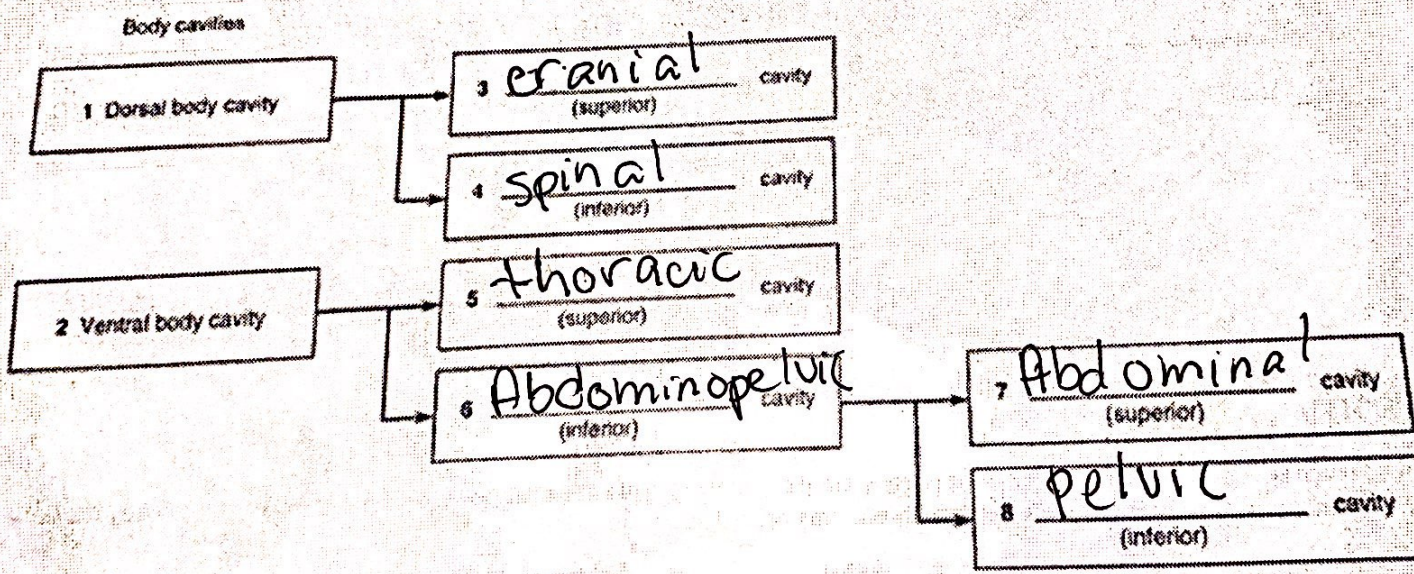
Key: a. abdominopelvic b. cranial c. dorsal d. spinal e. thoracic f. ventral

- E ~~B~~ ~~B~~ 1. surgery to remove a cancerous lung lobe
- A ~~B~~ ~~B~~ 2. removal of the uterus, or womb
- B ~~B~~ ~~B~~ 3. removal of a brain tumor
- ~~B~~ A 4. appendectomy
- A 5. stomach ulcer operation
- ~~B~~ 6. delivery of pre-operative "saddle" anesthesia

11. Name the muscle that subdivides the ventral body cavity. Diaphragm
12. Which organ system would not be represented in any of the body cavities? In tegumentary
13. What are the bony landmarks of the abdominopelvic cavity? Posteriorly, the vertebral column, laterally and anteriorly the ribs
14. Which body cavity affords the least protection to its internal structures? Abdominal
15. What is the function of the serous membranes of the body? The serous membrane produce a lubricating fluid (serous fluid) that reduces friction as an organs slide across one another or against the cavity wall during their function.
16. Using the key choices, identify the small body cavities described below.
- Key: a. middle ear cavity      c. oral cavity      e. synovial cavity  
 b. nasal cavity              d. orbital cavity
- D 1. holds the eyes in an anterior-facing position  
A 2. houses three tiny bones involved in hearing  
B 3. contained within the nose  
C 4. contains the tongue  
E 5. lines a joint cavity

17. On the incomplete flowchart provided below:

- Fill in the cavity names as appropriate to boxes 3-8.
- Then, using either the name of the cavity or the box numbers, identify the descriptions in the list that follows.



- |                |    |   |                       |    |                              |
|----------------|----|---|-----------------------|----|------------------------------|
| <u>Dorsal</u>  | a. | contained within the skull and vertebral column | <u>Thoracic</u>       | e. | contains the heart           |
| <u>Pelvic</u>  | b. | houses female reproductive organs               | <u>Abdominal</u>      | f. | contains the small intestine |
| <u>Cranial</u> | c. | the most protective body cavity                 | <u>Thoracic</u>       | g. | bounded by the ribs          |
| <u>Ventral</u> | d. | its name means belly                            | <u>Abdominopelvic</u> | h. | its walls are muscular       |

NAME Cherrina Campbell  
 LAB TIME/DATE \_\_\_\_\_

## Organ Systems Overview

1. Use the key below to indicate the body systems that perform the following functions for the body. Then, circle the organ systems (in the key) that are present in all subdivisions of the ventral body cavity.

- Key: a. cardiovascular      d. integumentary      g. nervous      j. skeletal  
 b. digestive              e. lymphatic/immunity      h. reproductive      k. urinary  
 c. endocrine              f. muscular              i. respiratory

- Urinary      1. rids the body of nitrogen-containing wastes
- Endocrine      2. is affected by removal of the thyroid gland
- Skeletal      3. provides support and levers on which the muscular system acts
- Cardiovascular      4. includes the heart
- Reproductive      5. causes the onset of the menstrual cycle
- Digestive      6. protects underlying organs from drying out and from mechanical damage
- Digestive      7. protects the body; destroys bacteria and tumor cells
- Digestive      8. breaks down ingested food into its building blocks
- Nervous      9. removes carbon dioxide from the blood
- Respiratory      10. delivers oxygen and nutrients to the tissues
- Muscular      11. moves the limbs; facilitates facial expression
- Endocrine      12. conserves body water or eliminates excesses
- Reproductive and Endocrine      13. facilitate conception and childbearing
- Nervous      14. controls the body by means of chemical molecules called hormones
- Lymphatics      15. is damaged when you cut your finger or get a severe sunburn

2. Using the above key, choose the organ system to which each of the following sets of organs or body structures belongs.

- Lymphatic      1. thymus, spleen, lymphatic vessels
- Skeletal      2. bones, cartilages, tendons
- Endocrine      3. pancreas, pituitary, adrenals
- Respiratory      4. trachea, bronchi, alveoli
- Integumentary      5. epidermis, dermis, and cutaneous sense organs
- Reproductive      6. testis, ductus deferens, urethra
- Digestive      7. esophagus, large intestine, rectum
- Muscular      8. muscles of the thigh, postural muscles

3. Using the key below, place the following organs in their proper body cavity.

Key:

- |                             |                             |                         |                     |
|-----------------------------|-----------------------------|-------------------------|---------------------|
| a. abdominopelvic           | b. cranial                  | c. spinal               | d. thoracic         |
| <u>A</u> 1. stomach         | <u>A</u> 4. liver           | <u>A</u> 5. spinal cord | <u>d</u> 7. heart   |
| <u>d</u> 2. esophagus       | <u>A</u> 6. urinary bladder |                         | <u>d</u> 8. trachea |
| <u>A</u> 3. large intestine |                             |                         | <u>A</u> 9. rectum  |

4. Using the organs listed in question 3 above, record, by number, which would be found in the abdominal regions listed below.

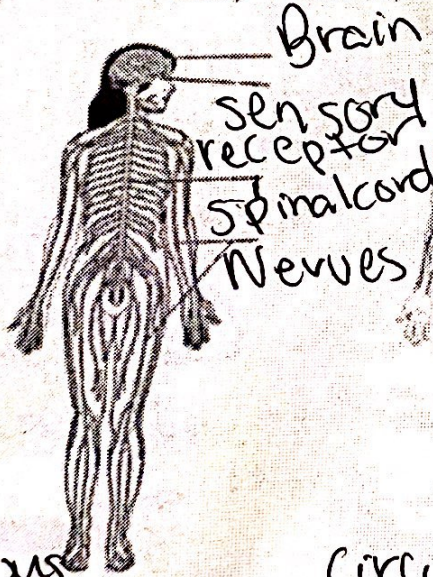
- |                                 |                                       |
|---------------------------------|---------------------------------------|
| <u>6</u> 1. hypogastric region  | <u>1</u> 4. epigastric region         |
| <u>3</u> 2. right lumbar region | <u>3</u> 5. left iliac region         |
| <u>1</u> 3. umbilical region    | <u>4</u> 6. left hypochondriac region |

5. The levels of organization of a living body are chemical, cellular, organ, organ system, and organism.

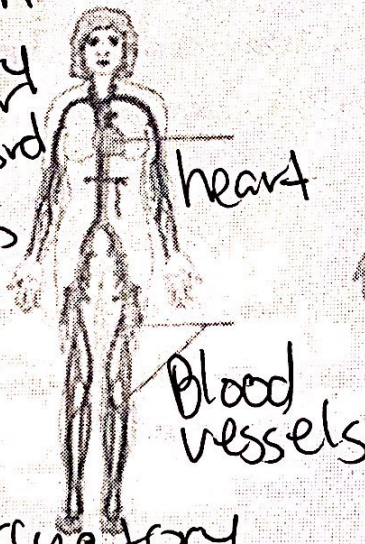
6. Define organ. A collection of tissues that structurally form a functional unit specialized to perform a particular function.

7. Using the terms provided, correctly identify all of the body organs provided with leader lines in the drawings shown below. Then name the organ systems by entering the name of each on the answer blank below each drawing.

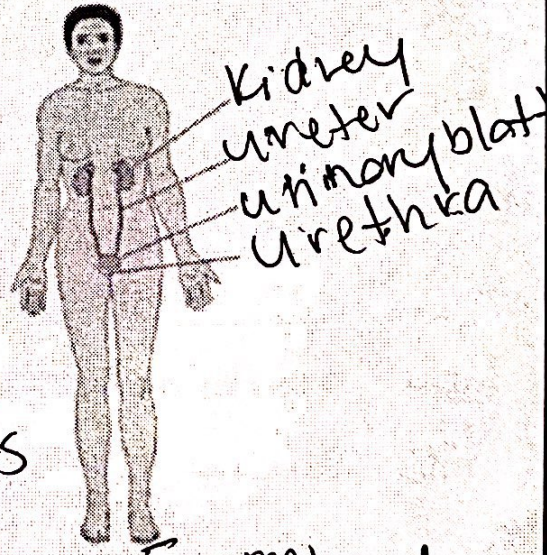
- Key: blood vessels    heart    nerves    spinal cord    urethra  
 brain    kidney    sensory receptor    ureter    urinary bladder



a. Nervous system



b. Circulatory system



c. Excretory system

8. Why is it helpful to study the external and internal structures of the rat? Many external and internal are very similar to a human and can help us understand our own structure.