

Lab 3 – Cardiovascular Physiology I

Learning Outcomes

- Describe the intrinsic conduction system of the heart.
- Describe the various components of a typical EKG.
- Connect the components of a typical EKG to activities of the heart.
- Define important terms connected like tachycardia, bradycardia, fibrillation, arrhythmia.
- Be able to obtain ECG recordings.
- Identify and interpret the different components of a typical EKG.

This lab covers the intrinsic conduction of the heart. Basically, it discusses what is involved in getting the heart to do what it does. The nervous system, like other organs systems and parts of the body, coordinates and communicate with the heart. However, the heart has its own control or intrinsic conduction system. This intrinsic conduction system controls the contraction and relaxation of the heart, which in term allows the heart to receive and pump blood to the body. The main parts of this conduction system are the sinoatrial node or SA node, the atrioventricular node or AV node, the bundle of HIS, bundle branches, and Purkinje fibers. Signals generated from the SA node will be propagated to the AV node and eventually to the Purkinje fibers which by then will coordinate the contraction of the ventricles. Unlike skeletal and smooth muscles, cardiac muscles are capable of initiating action potentials that will enable them to contract without the outside help of the central nervous system. This is referred to as automaticity. Let's take a closer look at the cardiac intrinsic conduction system.

The Cardiac Intrinsic Conduction System

The heart muscle cells can contract without input from the CNS. The heart has its own integrated conduction system which initiates and directs contraction of both atria and ventricles. These cells are special cells known as pacemaker cells or conducting cells. They have capabilities that are different from regular cardiac myocytes. Regular myocytes can contract and relax but are limited to in initiating their own contraction. In contrast, pacemaker cells have an innate ability to contract on their own. This is known as automaticity. Initiation of normal activity begins with the SA node. It is located in the walls of the right atrium. The impulses, once initiated follow a set path. From the SA node impulses will be transmitted to the AV node. This transmission is not immediate. There is a short delay, about 50 ms, from the time it is initiated at the SA node until it passes over to the AV node via the intermodal pathway. This delay is essential to allow the atria to contract. Both atria must contract and relax at the same time. After the SA node initiates the impulse it passes over to the left atrium via the **Bachmann's bundle**. Once the AV node receives the impulse it passes it over to the bundle of His, after a short delay, which will them transmits it over to the left and right bundle branches located in the interventricular septum. These bundle branches will transmit to the Purkinje fibers located in the ventricular walls. The impulses in the Purkinje fibers will initiate and complete the contraction of the ventricles. The right ventricle has a special muscular connection between the interventricular septum and the left ventricular wall called the moderator band, which help in transmitting impulses to the ventricular walls. The impulses from the interventricular septum will also be passed on to papillary muscles to prevent prolapsing of the AV valves during ventricular contraction.

Electrocardiogram and Heart Activities

Contraction of the heart depends on electrical activity initiated by the SA node. Similarly, the nervous system also depends on electrical activities when transmitting impulses. Both cardiac cells and skeletal muscles undergo depolarization followed by repolarization during an action potential. However; cardiac cells, unlike skeletal muscle cells, have a more rapid depolarization and a plateau phase.

Cardiac muscle cells also have a longer refractory period which is essential for efficient contraction and pumping of blood. Like skeletal muscles, depolarization occurs during the influx of Na⁺ into the cells. Within 3-5 ms Na⁺ channels close followed by opening of Ca²⁺ channels. These channels remain open and influx of Ca²⁺ into the cells lead to the plateau phase during cardiac cell action potential. Eventually these Ca²⁺ channels will close and K⁺

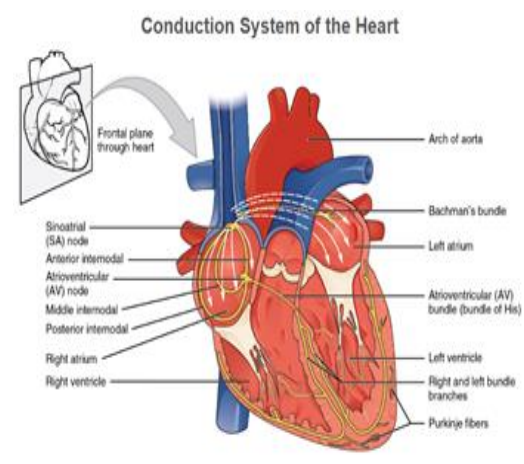


Figure 1: Conduction system of the heart. Anterior view of the heart showing the components of the conduction system of the heart. Credit OpenLab Anatomy and Physiology CC BY 3.0

channels will open allowing K^+ to exit the cells resulting in repolarization. During a cardiac cell's action potential there is a period when another action potential will not be able to be generated because Na^+ channels will not be able to respond other stimulus, because they are open, closed or are inactivated. This is known as the **absolute refractive period**. This delay in repolarization is necessary to allow the contraction of the heart to occur and be efficient. Immediately following this absolute refractive period, is a point when, depending on the intensity of the stimulus, another action potential can be generated if it is strong enough. This period is known as the **relative refractive period**. It is important to note that other components of the intrinsic conduction system are also able to initiate impulses on their own, although at a slower pace than the SA node. For instance, if the SA node is unable to function as a result of coronary artery diseases, the other components of the intrinsic conduction system will be able to depolarize and initiate action potentials, but at a slower pace.

The electrical activity of the heart can be recorded using electrocardiogram (ECG), also known as EKG. This has been a very important instrument to diagnose heart conditions. The readings picked up by electrodes placed on a patient, is transmitted to an instrument capable of displaying representations of the different heart electrical activities. These activities translate to contraction and relaxation of heart walls and chambers. On an ECG, there are waves, complexes, intervals and segments. Waves can be positive, above the straight line or isoelectric line, or negative, below the isoelectric line. More than one consecutive wave makes a complex. Distance between two waves is a segment, while one or more waves and a segment is known as intervals. Each feature of the ECG represents different heart activities. The P wave represents atrial depolarization. The QRS complex, which includes three waves (QRS), represents depolarization of the ventricles. Depolarization is not contraction but will lead to contraction. The third wave, usually positive, represents repolarization of the ventricles; an event that will lead to relaxation of the ventricles. Repolarization of the atria takes place, but it is not seen on an ECG because it is masked by the bigger QRS. Other components include PR interval, from the start of the P wave to the start of the Q wave; the P segment, from the end of the P wave to the start of the Q wave; the ST segment, from the end of the S wave to the start of the T wave; the QT interval, from the start of Q wave to the end of T wave. The table below gives the various interpretations of segments and intervals seen on an ECG. Also given are the normal values for each component. Interpretation of ECG also relies on the duration of each of these components. There is a normal range for each component. Deviation from these ranges can be indicative of conditions affecting the normal function of the heart. To facilitate reading and interpretation of an ECG, the strip or paper is divided into squares. On an ECG stripe each small square represents 0.04 sec. and one large square represents 0.2 secs.

Heart rate can be calculated, if the heart rate is regular, by dividing 1500 (# of small squares in a minute) by the number of small squares between two R waves (or 2 P waves) or dividing 300 by the number of large squares. See examples below.

1500/# of small squares
If there are 22.5 small squares between two RR intervals,
then the heart rate will be
 $1500/22.5 = 66.66$

300/#of large squares
If there are 4.5 large squares, then the heart rate will be
 $300/4.5 = 66.6$

If the rhythm is irregular then one can count the number of RR intervals in 6 sec (30 large squares) and multiply by 10.

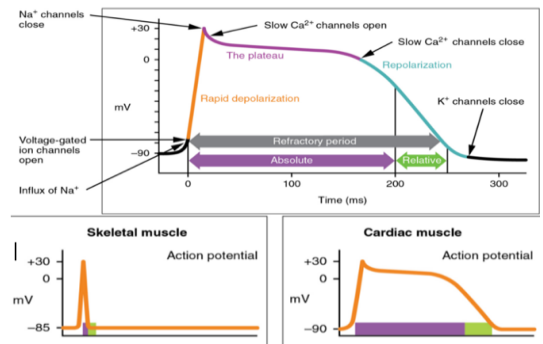


Figure 2: Action potential of cardiac and skeletal muscle. (A) Typical action potential in cardiac muscles, (B) action potential of skeletal muscles compared to cardiac muscles. (credit: OpenLab Anatomy and Physiology CC BY 3.0)

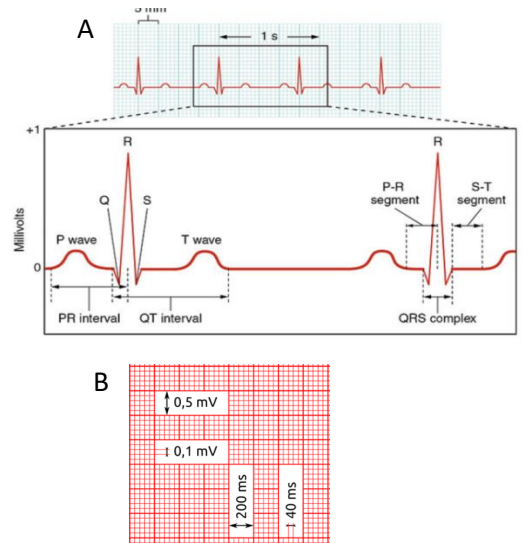


Figure 3: ECG tracing and components. (A) ECG showing the various components of a typical ECG. (B) Duration and voltage of each small and large square (Credit (A) OpenStax Anatomy and Physiology (CC BY 3.0), (B) Public Domain)

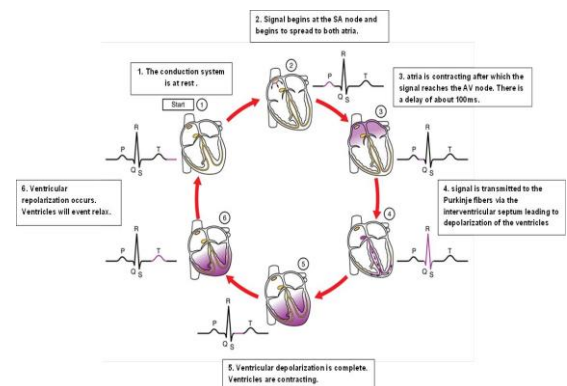


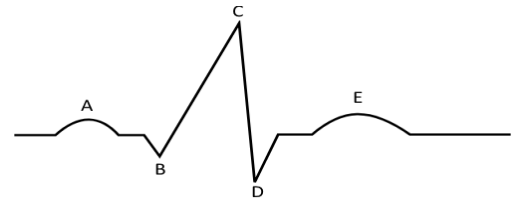
Figure 4: ECG tracing and components. (A) ECG showing the various components of a typical ECG. (B) Duration and voltage of each small and large square (Credit (A) OpenStax Anatomy and Physiology, (B) Public Domain)

Normal heart rate is between 60 – 100 bpm, however average resting heart rate is in the 70s for both men and women. Heart rates below 60bpm are referred to as **bradycardia** and rate above 100bpm is **tachycardia**.

Activity 1. The ECG

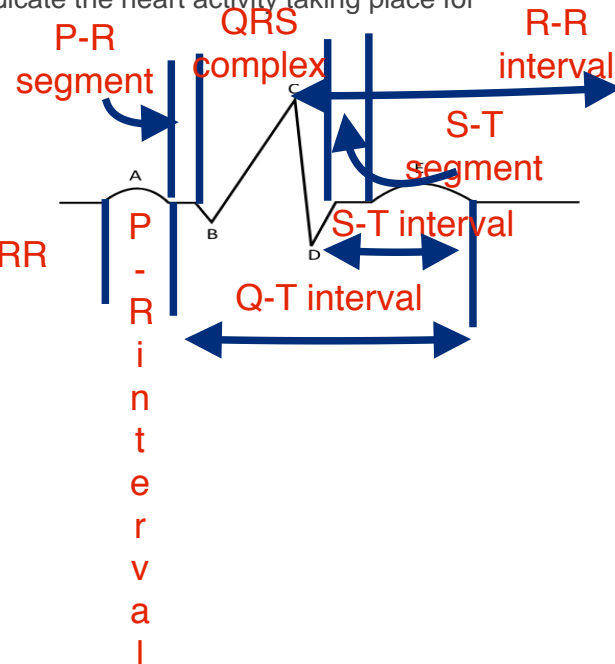
1. Label the following EKG wave and give the heart activity taking place.

- A. P Wave
- B. Q Wave
- C. R Wave
- D. S Wave
- E. T Wave



2. Using vertical lines show the following segments and intervals and indicate the heart activity taking place for each.

- A. P-R interval ✓ _____
- B. P-R segment ✓ _____
- C. QRS complex ✓ _____
- D. S-T segment ✓ _____
- E. S-T interval ✓ _____
- F. R-R interval ✓ From 1st R wave to second is the RR interval
- G. Q-T interval ✓ _____



3. What does each of the following distances indicate?

- A. One small square 1mm-40ms , 0.04s
- B. 5 small squares 5mm-200ms
- C. One large square 300bpm
- D. 4 large squares 74bpm
- E. 5 large squares 60bpm
- F. 15 large squares 100bpm

Conditions involving irregular heart activities

- **Cardiac arrhythmias or Irregular heart rate** – deviation from normal heart rate.
 - **Atrial fibrillation (A-fib)** – absence of P wave. Atria and ventricle activity are not coordinated.
 - **Ventricular fibrillation (V-fib)** – uncoordinated activities or contraction of the ventricles
 - **Premature ventricular contractions (PVCs)** – “skipped heartbeat” sensation. There is an extra heartbeat in the ventricles.
 - **Bradycardia** – Abnormally low heart rate (less than 60 bpm)
 - **Tachycardia** – Abnormally high heart rate (above 100 bpm)
- **Heart blocks** – impairment of electrical conduction from the SA node to the purkinje fibers. May be of different types depending on the affected area.
 - **First-degree heart block** – slow electrical impulses through the conduction system
 - **Second-degree heart block** – signals are unable to reach the ventricles.
 - **Third-degree heart block** – complete blockage. Electrical impulses do not reach the ventricles.
- **Long QT syndrome (LQTS)** – The QT interval is longer than normal indicating the ventricles are taking longer to contract and relax.
- **Left and right ventricular hypertrophy** – enlargement of the ventricles. Several criteria such as deep S wave, tall R wave, abnormal QRS complex.

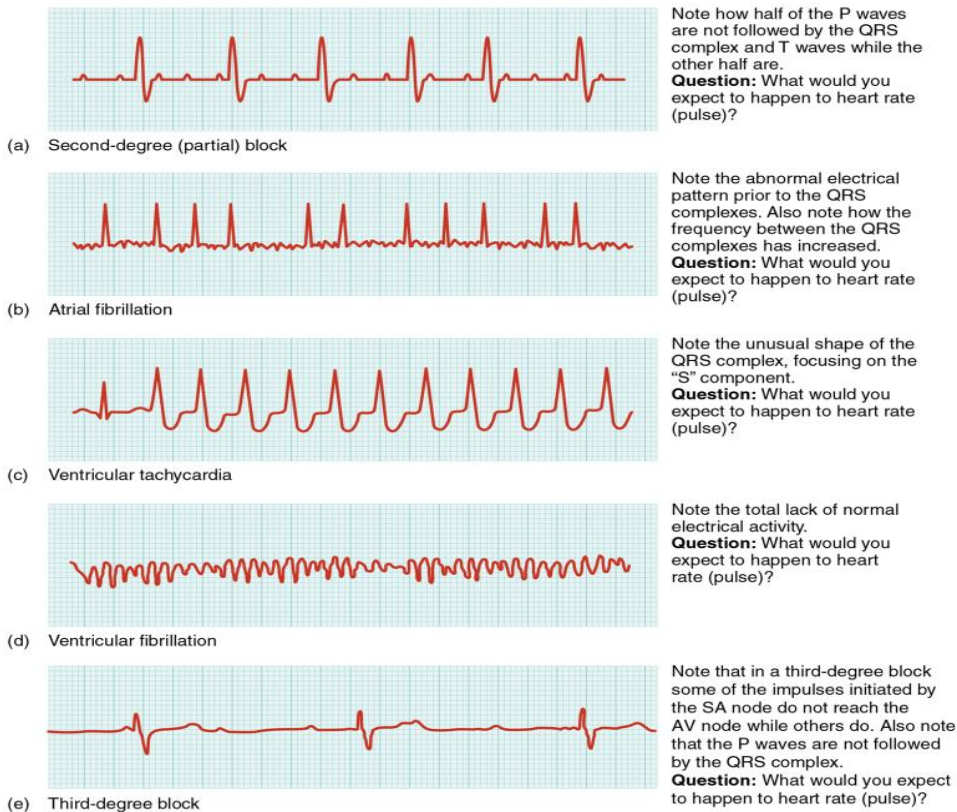
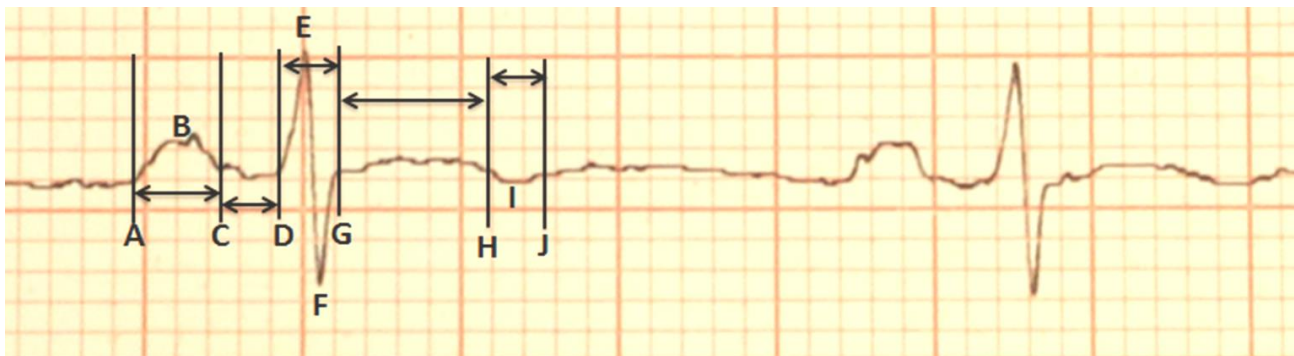

Figure 5: Common ECG abnormalities. Examples of different abnormalities seen on an ECG. (Credit: OpenStax Anatomy and Physiology, CC BY 3.0)

Component	Electrical activity	Normal range (sec)
P wave	Atrial depolarization	0.06-0.11
P-R interval	Time from atria depolarization to depolarization of the ventricles	0.12 – 0.22
P-R segment	Time between atrial depolarization and start of ventricular depolarization	0.012-0.20
QRS	Depolarization of the ventricles	0.06-0.10
T-wave	Repolarization of the ventricles	0.160, upright
S-T segment	Early part of ventricular depolarization	0.08-0.12
Q-T interval	Time the ventricle depolarize and repolarize	0.36-0.44

Table 1: ECG components and normal ranges

Activity 2 – Interpreting an EKG graph.



Using the above ECG, give the following measurements for each of the following. Indicate if each one is in the normal range.

Calculate the heart rate, assuming this EKG is regular.

EKG Features	Normal range	Measured value	Comments (normal or abnormal)
A-C	0.12-0.22		
B	0.06-0.11		
C-D	0.012-0.20		
E	0.06-0.10		
F	0.06-0.10		
D-G			
G-H			
I			
G-J			
T-P segment			

Measuring electrical activity of the heart – EKG

A typical EKG machine has 12 leads (angles) calculated using 10 electrodes. These electrodes are placed on the body to measure the heart's electrical activities. In this lab we will only make use of 3 to four electrodes which will be used to determine three leads (I-III). These leads will then be used to determine the heart activity. The three leads form what is known as **Einthoven triangle**, it is presumed that the heart is at the center of this triangle. The electrodes to be used will be; one electrode on the right arm (RA), one on the left arm (LA), one on the left leg (LL) and one on the right leg (RL). If the RL is not available, the three others will do. The leads are as follows;

- Lead I – connects right arm to left arm -
- Lead II – connects right arm to left leg – ideal for examining the various waves or deflections.
- Lead III – connects left arm to left leg

After the electrodes have been set and the readings have been taken, a printout of the readings will be given. Description of the squares and measurements has been described previously. To get good readings follow these particular guidelines.

1. Be sure to be still when the readings are being taken.
2. Remove watches and other metals to prevent interference.
3. Be sure to wait to give the instrument time to take the best reading.

Activity 3 – EKG measurements at various time points.

ECG can be measured using either the LapQuest 2 handheld device or the regular EKG instrument. If using the LabQuest2 follow the instructions given.

1. Recording Baseline Readings

1. Take an EKG of everyone in your group.
2. Select who will be the experimental subject is.
3. Take an average of three separate readings. Use a ruler to measure the various regions.

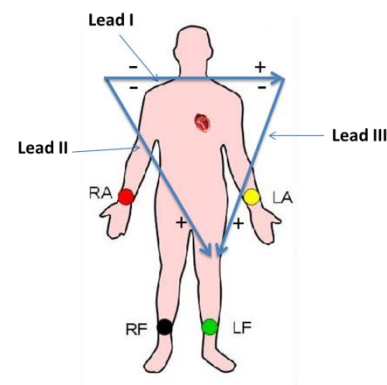


Figure 4. Placement of electrodes and the Einthoven triangle (Blue arrows). (Credit: modified from Medic, CC BY-SA 3.0)

Component	Reading 1	Reading 2	Reading 3	Average
P wave				
T-wave				
S-T segment				
P-R interval				
P-R segment				
QRS				
Q-T				
R-R				
Heart rate (b/m)				

2. Effect of standing

Repeat the measurements with the test subject standing.

Component	Reading 1	Reading 2	Reading 3	Average
a. P wave				
b. T-wave				
c. S-T segment				
d. P-R interval				
e. P-R segment				
f. QRS				
g. Q-T				
h. R-R				
i. Heart rate (b/m)				

What are the effects of standing on each of the above?

3. Effect of exercise

Repeat the measurements after the test subject has exercised for 3 minutes. Be sure to have the electrodes in place so as to connect the leads as soon as the person is done exercising.

Component	Reading 1	Reading 2	Reading 3	Average
P wave				
T-wave				
S-T segment				
P-R interval				
P-R segment				
QRS				
Q-T				
R-R				
Heart rate (b/m)				

What are the effects of exercise on each of the above? Summarize your results in a paragraph form.

Repeat the measurement after 5 minutes of rest.

Component	Reading 1	Reading 2	Reading 3	Average
P wave				
T-wave				
S-T segment				
P-R interval				
P-R segment				
QRS				
Q-T				
R-R				
Heart rate (b/m)				

What was the overall effect of resting on the above readings? Describe what happened to each component.

Review Exercise

1. Match the term to its correct description.

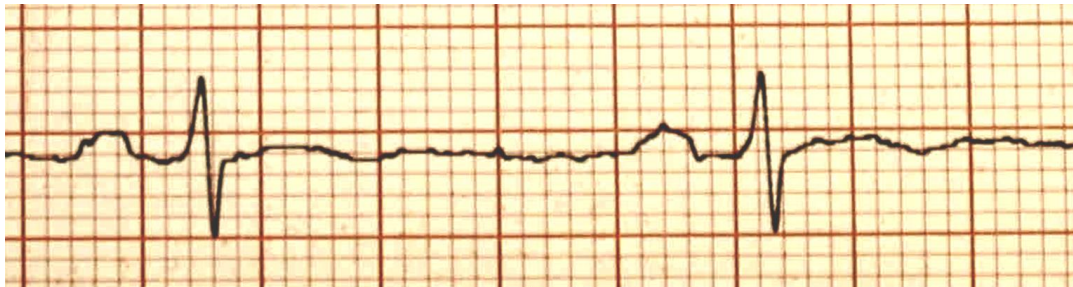~~SA~~ ~~Plateau~~ ~~AV~~ ~~Purkinje fibers~~ ~~bundle of His~~
~~AV bundles~~ ~~Absolute~~ ~~EKG~~ ~~IV septum~~ ~~Autorhythmic~~
~~Internodal~~ ~~Relative~~ ~~Calcium~~ ~~Depolarization~~ ~~Bachmann's bundle~~

- Autorhythmic** The ability of myocytes to contract on their own.
- Absolute** Na^+ is responsible for this phase of an action potential.
- Purkinje Fibers** Located in the interventricular septum.
- Depolarization** Responsible for the plateau phase seen in cardiac action potential.
- AV Bundles** Connects the bundle branches to the AV node.
- SA** Initiates the normal contraction of the heart.
- Bachmann's Bundle** Connects the SA node to the left atrium.
- Plateau** No action potential can be initiated at this phase.
- EKG** Used to diagnose certain cardiac disorders.
- Bundle of His** Problems with these will directly affect the ventricles.
- Calcium** Seen in cardiac action potential but not in skeletal action potential
- Internodal** These connect the SA node with AV node.
- AV** This directs the action potentials to the Bundle of HIS.
- IV Septum** location of the left and right bundles.
- Relative** Strong stimuli can initiate an action potential during this phase.

2. Compare and contrast skeletal muscles with cardiac muscles. For each characteristic given say whether they are found in one or both muscle types.

	Skeletal Muscles	Cardiac Muscles
Number of nucleus per cell	more than 1	1 or 2
Presence or absence of intercalated discs	absence	presence
Present or absent of striations	presence	presence
Voluntary or involuntary control	voluntary	involuntary
Typical cell size	40 mm	50-100 micrometers
Cells are branched or unbranched	unbranched	branched
Speed of contraction	fast	slow
Require calcium	require	require
Presence of plateau phase in action potential	absence	presence
Autorhythmic	absence	presence

2. Use the cardiogram below to determine duration of the following. Use the number of squares to calculate.



1. P wave _____
2. QRS complex _____
3. T wave _____
4. P-R interval _____
5. S-T segment _____
6. Q-T interval _____
7. T-P segment _____

3. Which feature or components of an ECG represents

- a) Ventricular contraction
- b) Repolarization of ventricles
- c) Time for impulse to travel from AV node to ventricles
- d) Atrial depolarization

QRS complex
T wave
P Wave
P and T Waves and QRS complex

4. A patient came in to the ER complaining of chest pain. An EKG was taken immediately. The following were some of the results obtained initially.

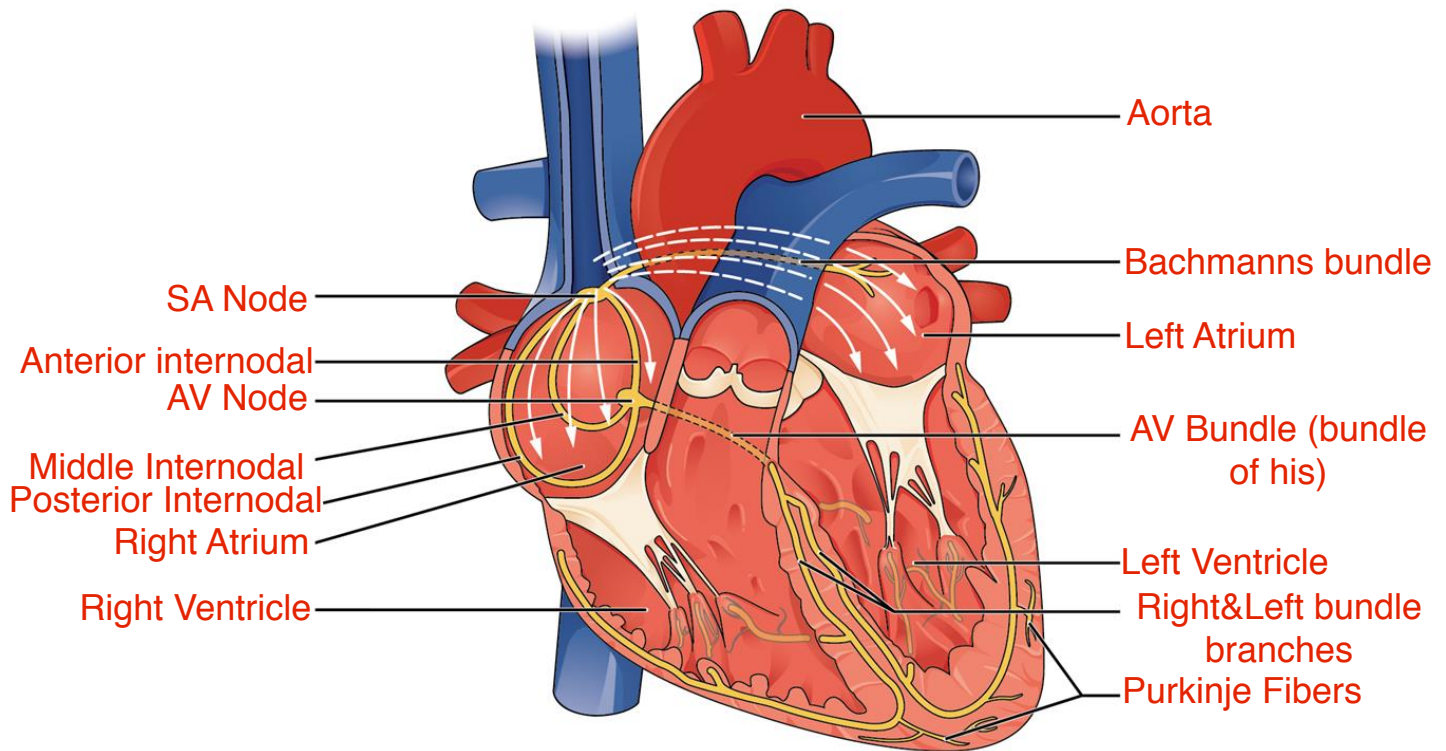
R-R intervals were 2 large squares.
Large QRS complex (>0.20)

PR interval is 0.30
abnormally long ST segments

List three heart conditions or abnormality associated with these results.

1. Cardiac arrest
2. coronary heart disease
3. electrolyte abnormality

3. Label the following diagram.



Research

Select one of the common cardiovascular diseases and, in one paragraph, describe causes, sign and symptoms, diagnosis and treatment.

Coronary Artery Disease

Coronary artery disease is caused by plaque buildup in the wall of the arteries that supply blood to the heart. Plaque is made up of cholesterol deposits. Plaque buildup causes the inside of the arteries to narrow over time.

Signs and symptoms of this diseases is Chest pain or discomfort, weakness, light-headedness, nausea (feeling sick to your stomach), or a cold sweat.

Pain or discomfort in the arms or shoulder.

Shortness of breath.

Diagnosis and treatment for this diseases include lifestyle changes, medications, angioplasty, and surgery (Coronary artery bypass surgery surgery that restores blood flow to the heart by using a healthy artery or vein to bypass a blocked artery).