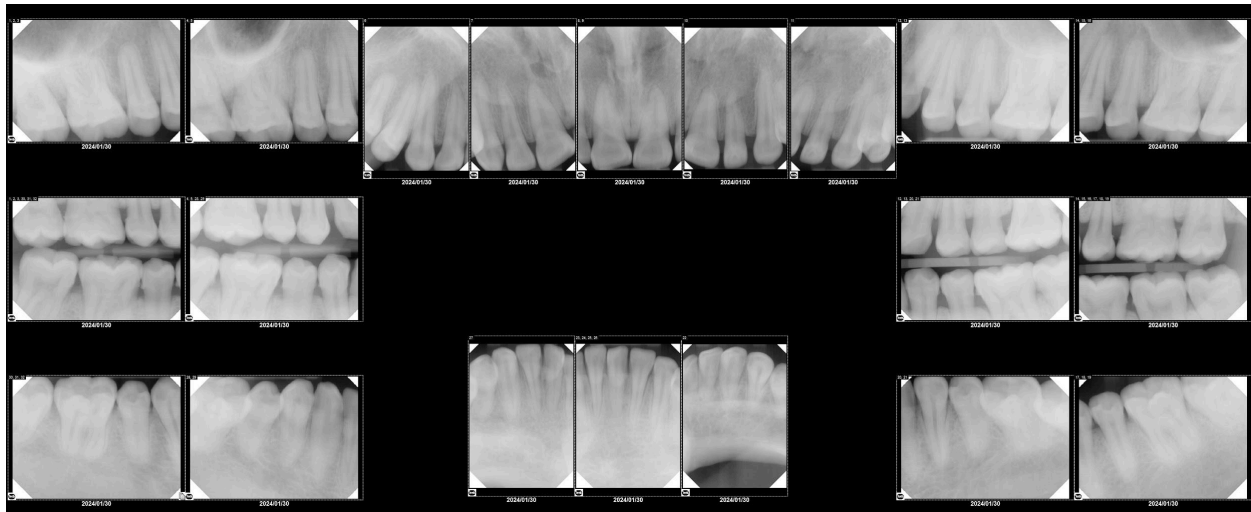


- **Case study 2:** Patient has very limited access to healthcare i.e. no PCP or registered dental home.
 - **Case study 2**
 - 29 year-old Hispanic Male
 - Patient visited to receive a regular cleaning
 - Health history overview:
 - Vitals: 126/83 ASA 2
 - Medical conditions: History of abdominal cancer in 2018 in which he underwent chemotherapy for approximately 1-year. Patient also reported having appendicitis as well as having their appendix removed in 2023 along with a chest x-ray. Patient also smokes ~1-2 cigarettes/day and consumes 1-3 alcoholic beverages/month.
 - Current medications: None
 - Dental History: Has not received a cleaning since 2020 and never received dental radiographs. Experiences sensitivity on entire dentition to the cold and bleeding gums during brushing.
 - Summary of clinical findings:
 - Dental charting: Bilateral class III, Overjet 2mm and Overbite 70%.
 - Incipient identified on teeth #18-O
 - Missing teeth #1, #16 and #32
 - Generalized mild attrition
 - Erosion on #4-O and #5-O
 - Localized abrasion due to harsh brushing on posterior molars
 - Mild generalized demineralization on occlusal surfaces of posterior teeth.
 - Diastema canine to canine on both arches.
 - Gingival description/Periodontal status:
 - Generalized moderate erythematous gingival. Marginal gingival is rolled and is located at CEJ with localized 2-4 mm GM apical to CEJ in mandibular anterior region. Localized bulbous interdental papilla on mandibular anterior teeth. Texture of gingiva is shiny with a mild soft puffy consistency.

- Periodontal status: Stage II Grade B
- Periodontal Charting: Generalized 2-3 mm PD with BOP. Localized 4-5 mm PD on local posteriors sextants along with 2-4 mm facial recession noted from #22-26.
- Radiographs: Exposed digital radiographs (FMS) at 7mA and 70kV on 1/30/2024.
- The following findings were observed: No signs of caries, generalized 15-20% HBL with localized 10% VBL between #19-20. Generalized radiographic calculus.



- Dental hygiene diagnosis:
 - Periodontal diagnosis: Generalized Stage I Grade B
 - Risk for caries: High due to root exposure and moderate erosion
- Dental hygiene care plan: PI index performed on patient, radiographs were exposed, local anesthetic needed for pain management, divided tx plan into 4 appointments for a full mouth cleaning, polish, 5% Fluoride Varnish and a referral given for hypertension.
- Challenges during treatment: Patients had severe generalized pain resulting in the need for several regional infiltrations. Maxillary torus and bilateral mandibular tori were in the way while taking FMS, the patient was in pain.

- Evaluation of care: Patient received full mouth SRP, homecare instructions, areas of previously observed gingival inflammation and bluntness reduced.
- Continued care recommendations:
Recommended patient to continue to use proxy interdental aids 2x/day for large embrasures on local mandibular sextant. Lastly, pt was recommended to continue implementing a fluoridated mouthwash such as ACT and Parodontax Gum Repair toothpaste in their home care 2x/day