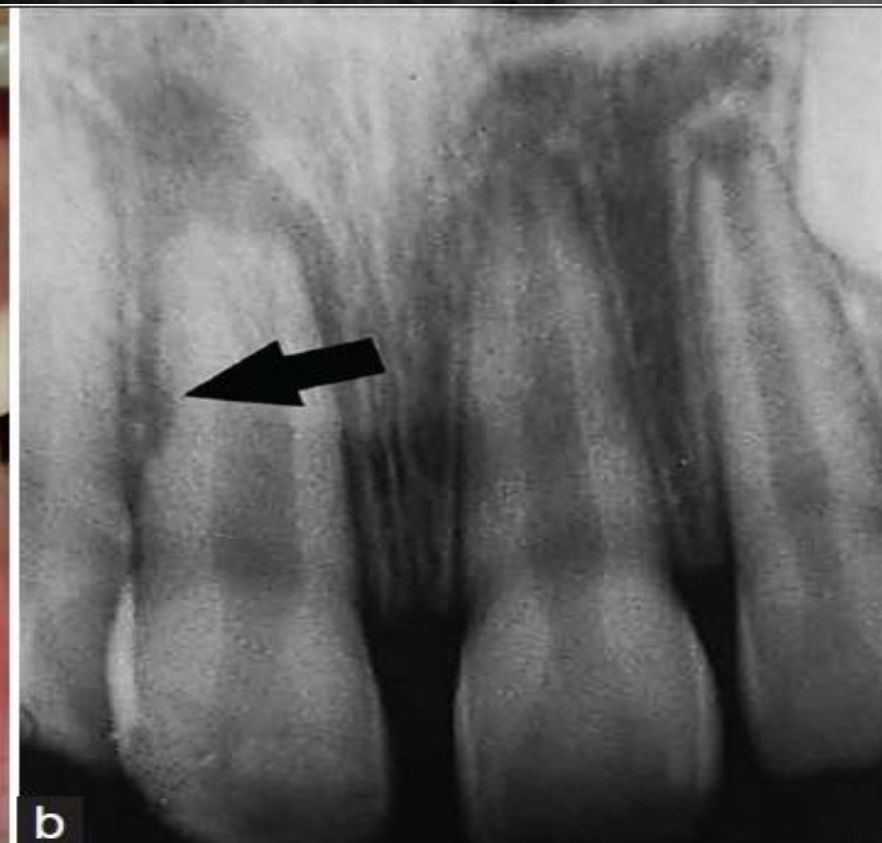
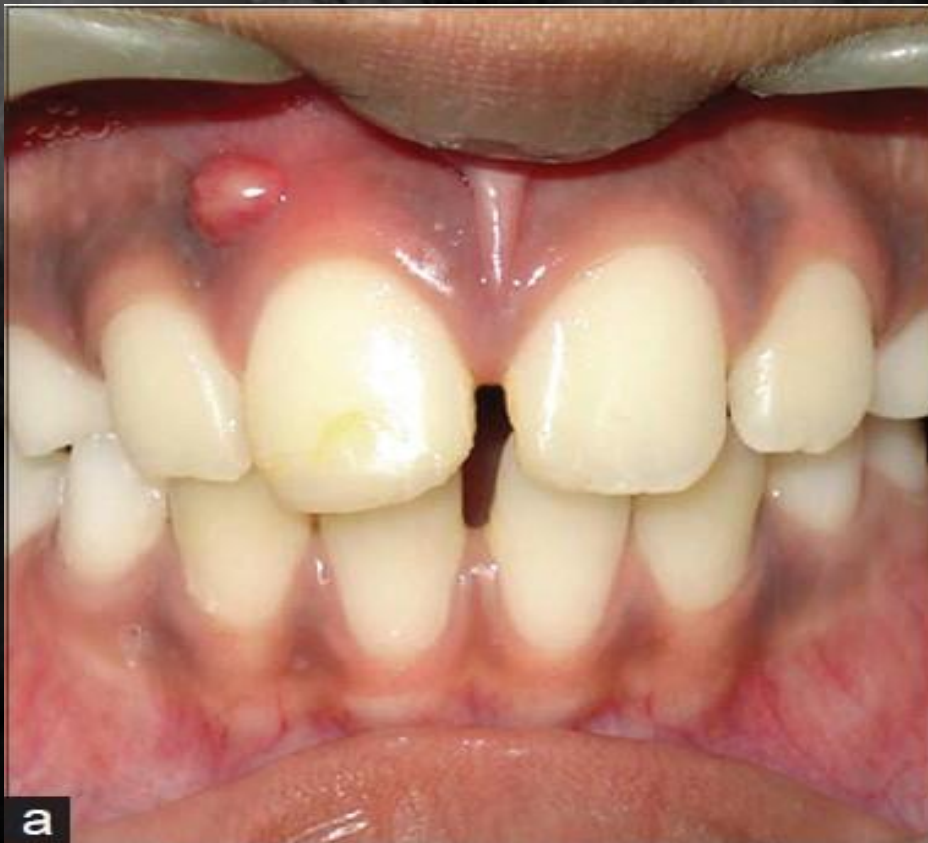


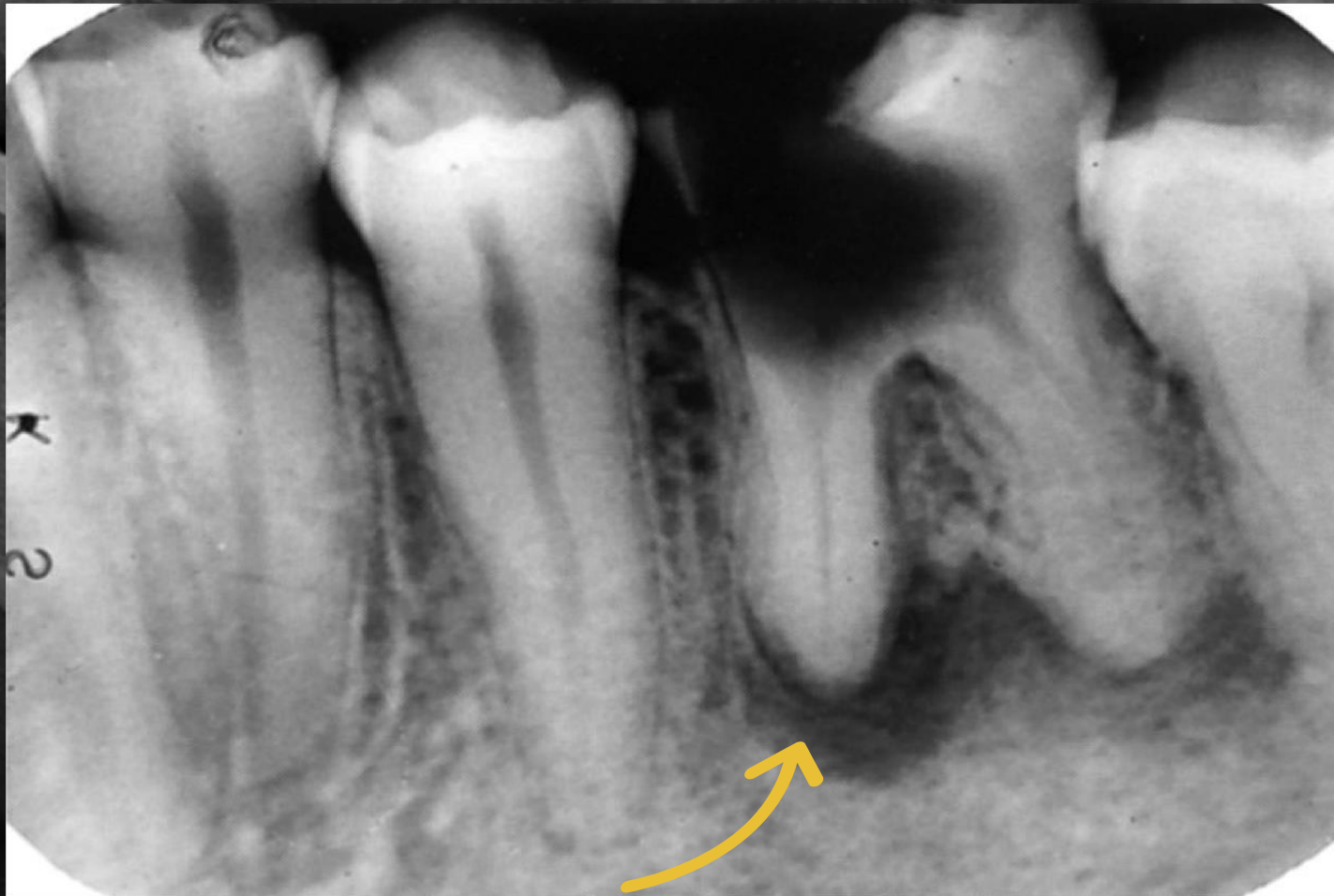Periapical Pathology

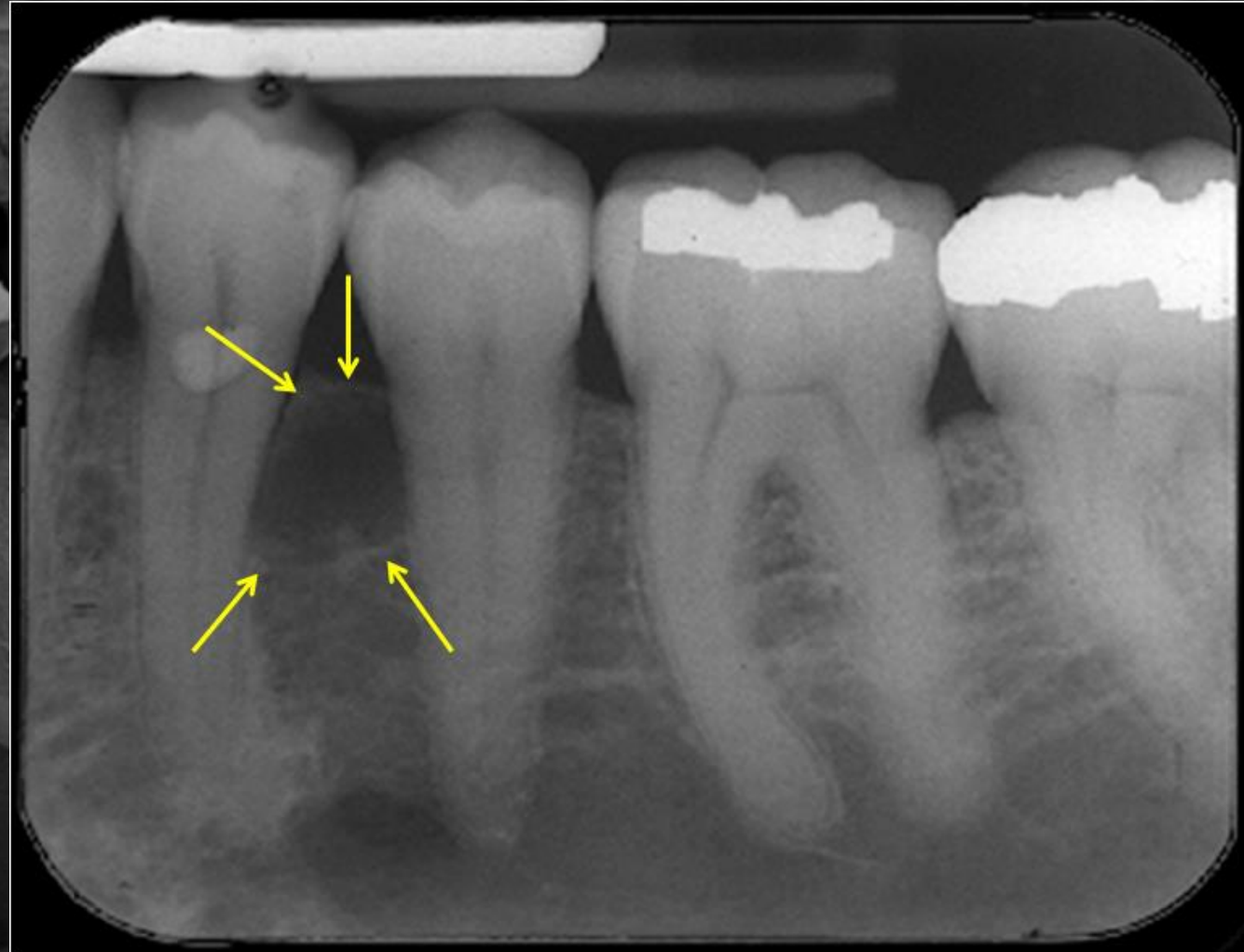
SEEN IN THIS DENTAL AND CLINICAL IMAGE
IS A PERIAPICAL ABSCESS ON MAXILLARY #8



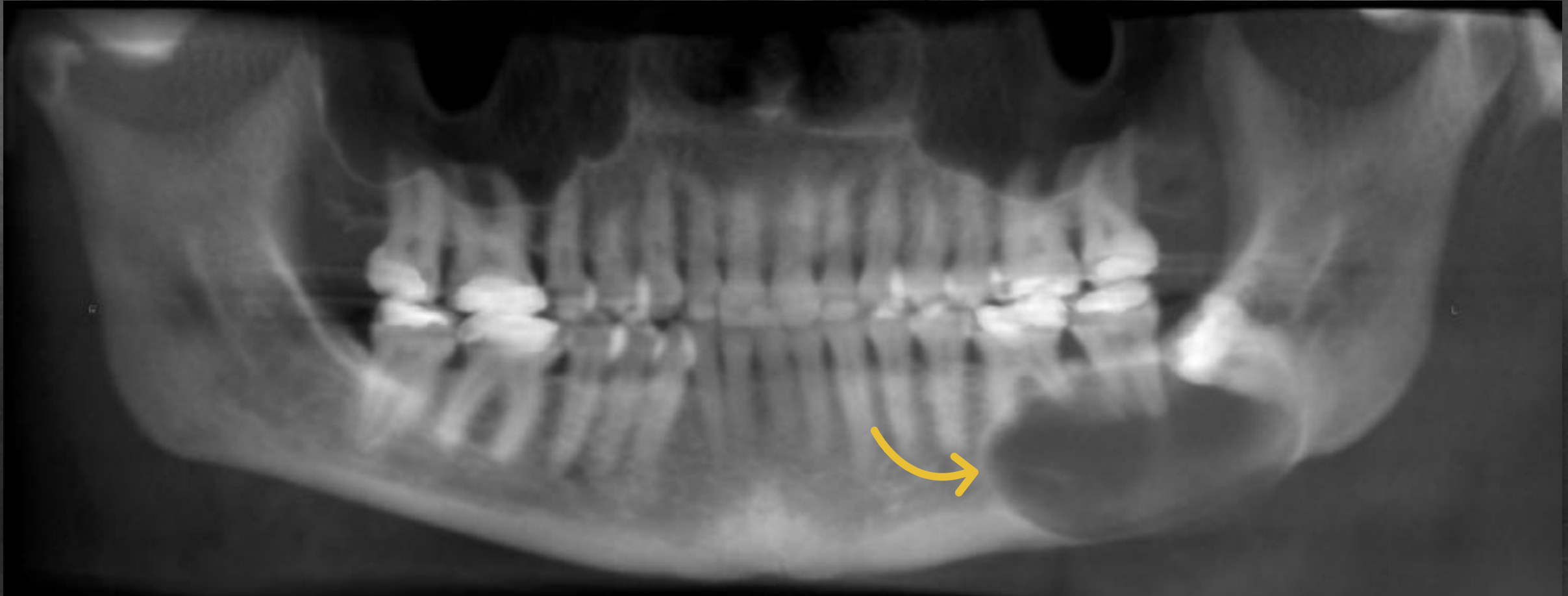
PICTURED HERE IS A GRANULOMA ON A MANDIBULAR FIRST MOLAR



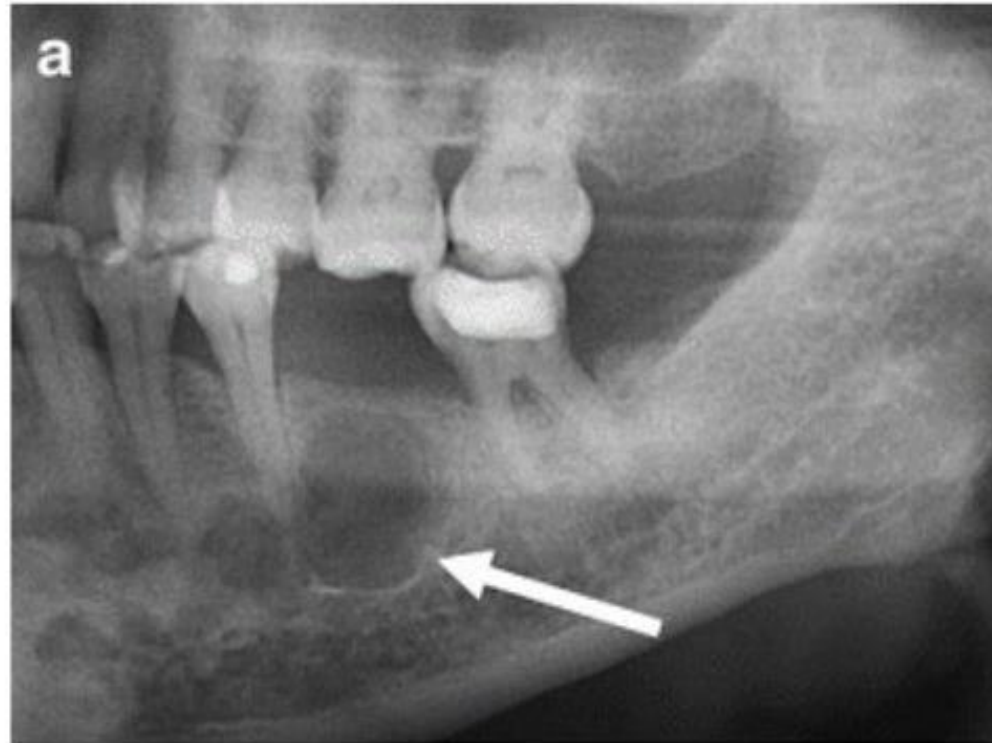
PICTURED HERE IS A PERIAPICAL THAT SHOWS A LATERAL PERIODONTAL CYST



VISUALIZED HERE IS A RADICULAR CYST
APICAL TO THE MANDIBULAR RIGHT MOLARS

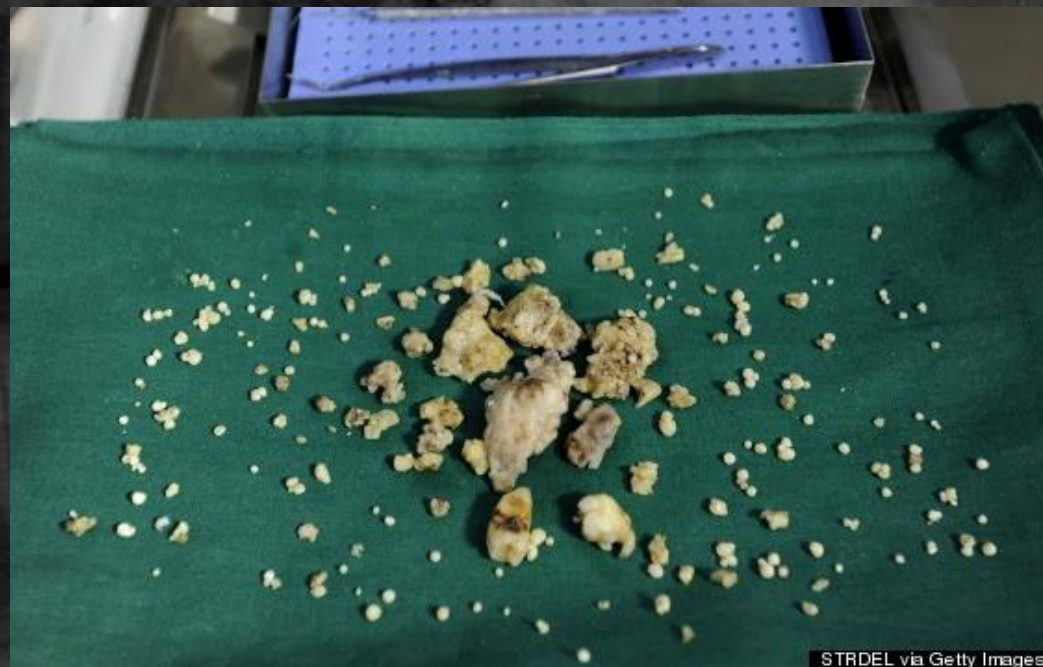
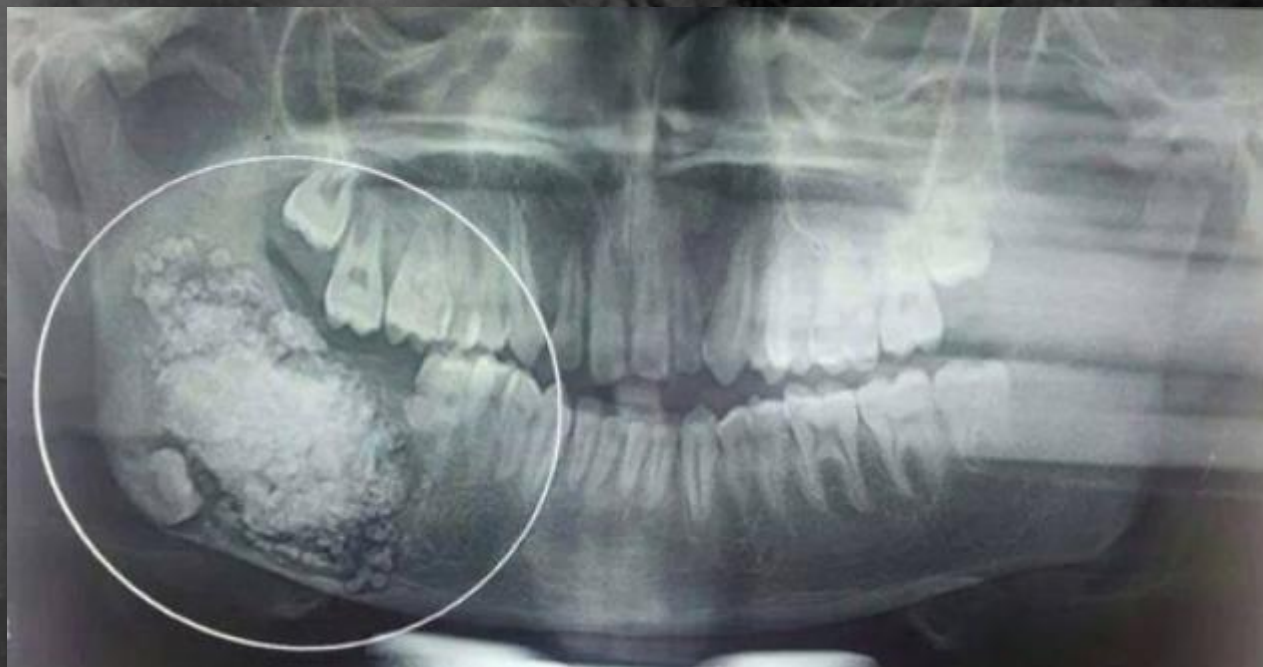
PICTURED HERE IS A RESIDUAL CYST WITH SCLEROTIC BORDERS



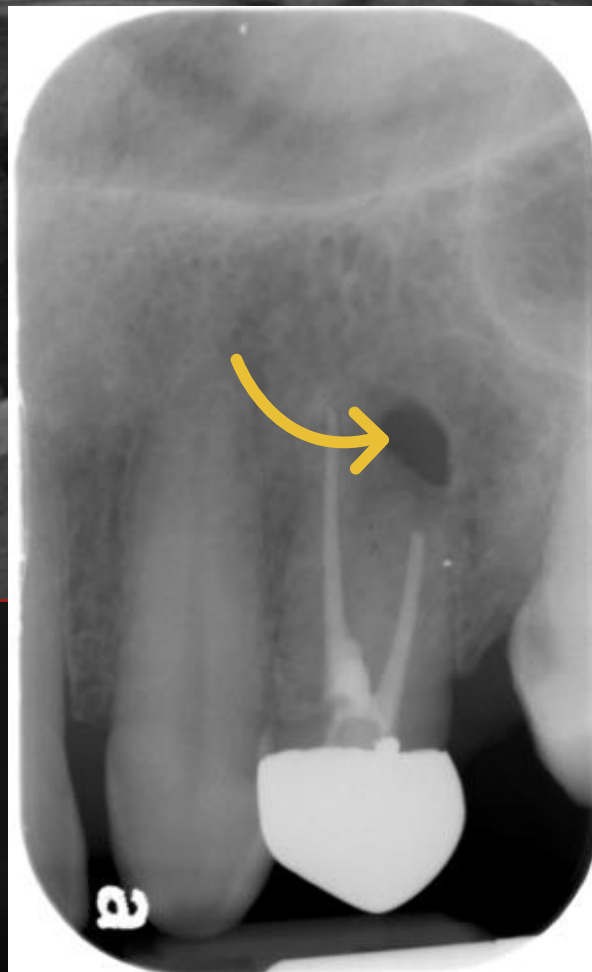
Residual cyst, Panorama x-ray shows unilocular well-defined lesion with sclerotic borders (arrow) and missing tooth 36 above

THIS PHENOMENON IS COMPLEX ODONTOMA



STRDEL via Getty Images

A PERIAPICAL SCAR IS VISIBLE IN THIS IMAGE



THIS IMAGE IS A CEMENTOMA (PERIAPICAL CEMENTAL DYSPLASIA) STAGE I, II & III,

