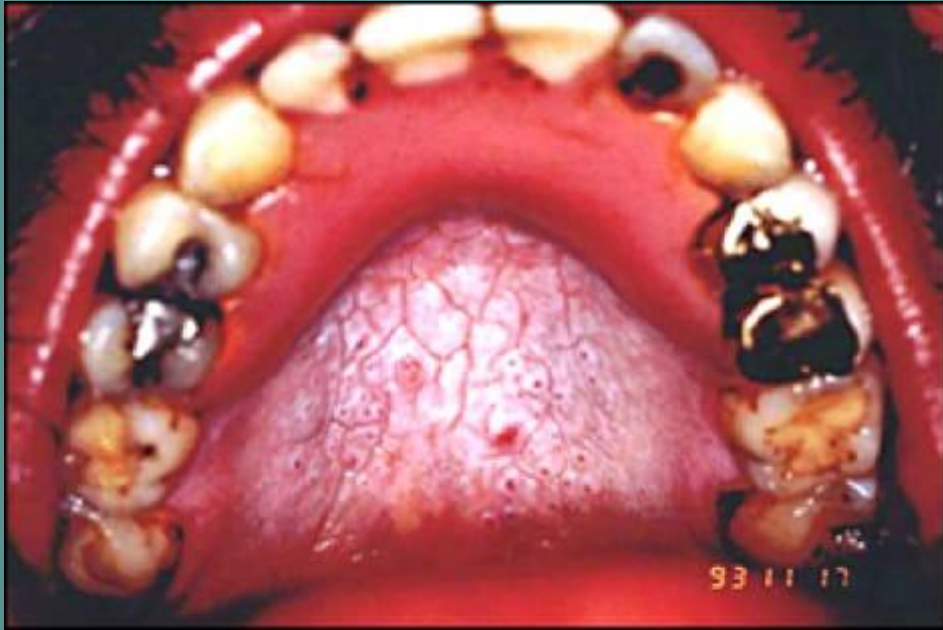

Nicotine Stomatitis

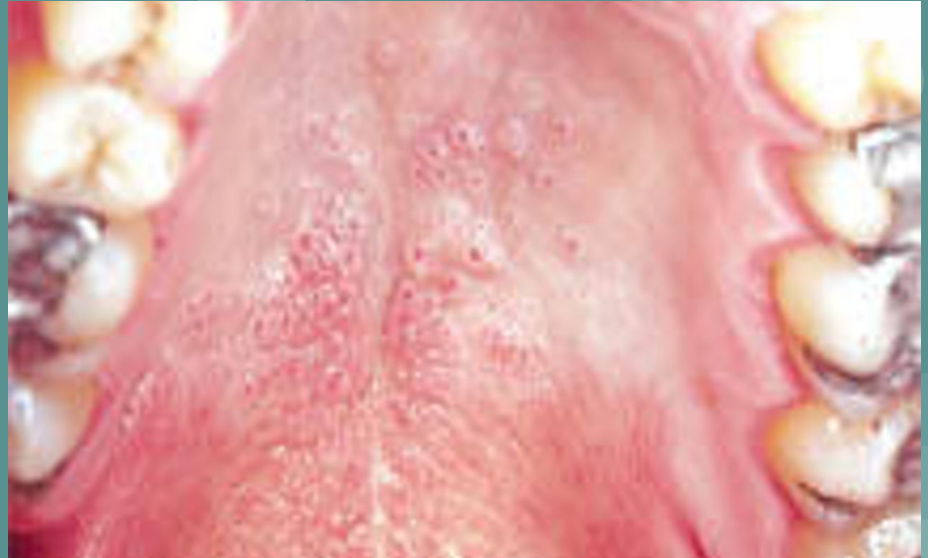

By Peiqiong Li

What is Nicotine Stomatitis?

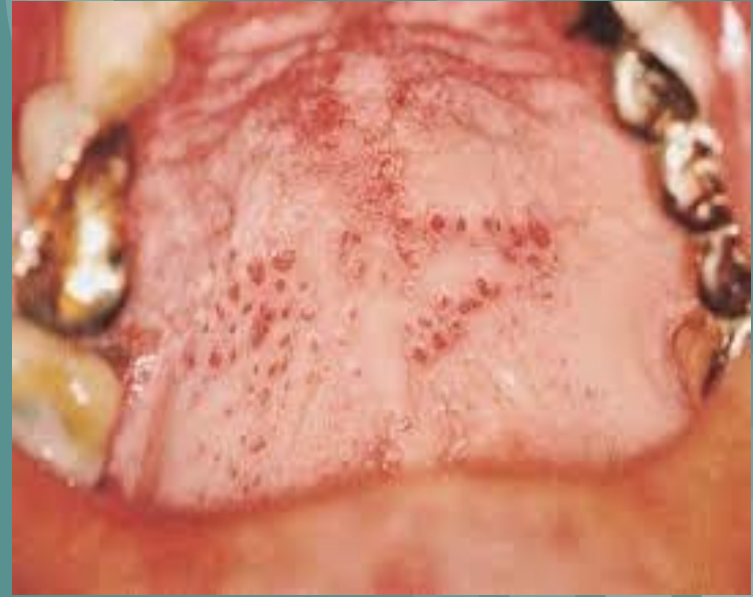Other names: smoker's palate, nicotinic stomatitis, stomatitis nicotina, or smoker's keratosis.

- ❖ Caused by cigar, tobacco pipe, and cigarette smoking.
- ❖ Heat arouses opacification of the palate.
- ❖ In general, hyperkeratosis appears in the hard palate with red dots, represent inflamed minor salivary duct openings.



Health effects

- ❖ Tobacco users have higher risk of cancer when nicotine stomatitis appeared: tonsils, posterior mouth, and lungs.
- ❖ Smoke reduces blood flow to the gum, and reduces saliva secretion.
- ❖ Thicker saliva, which does not protect the teeth, easier get teeth decay than non-smoker.
- ❖ Stained teeth, tongue, and gum discoloration.

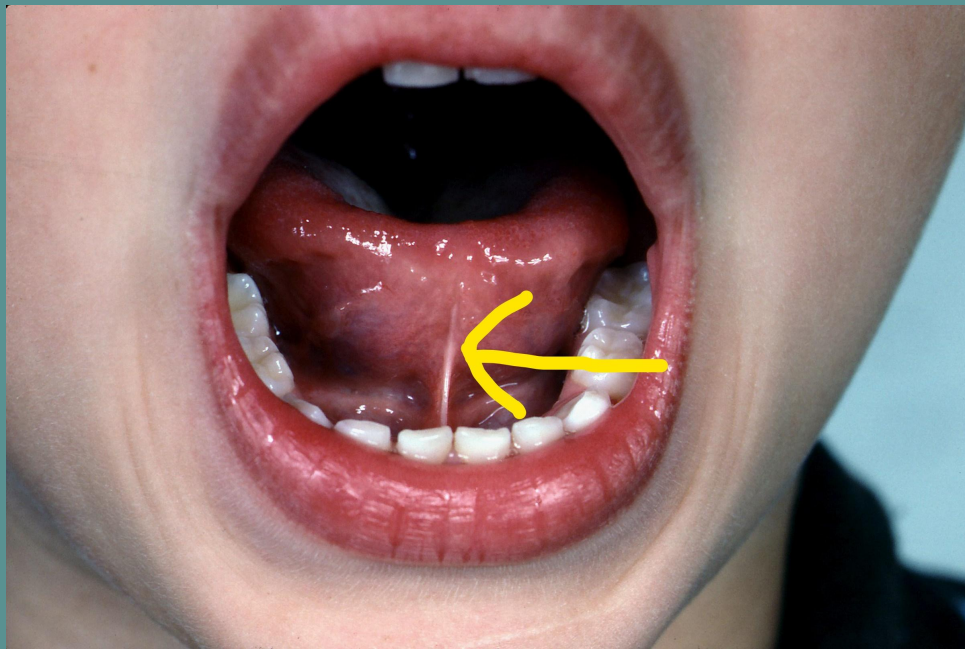


What to do?

- ❖ **Quit smoke**, the hard palate will return to normal within few weeks.
- ❖ Brush and floss your teeth regularly, your gum will be healthier and your breath will be fresher.
- ❖ Having dental check-up frequently.



Tongue Ankyloglossia



By Peiqiong Li

What is tongue ankyloglossia?

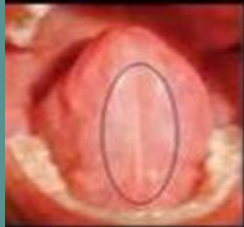- ❖ Also named tongue tie
- ❖ A strong membrane connect ventral surface of the tongue to the floor of the mouth
- ❖ Congenital abnormal short, thick lingual frenulum that decrease mobility of the tongue tip
- ❖ Improper tongue movements affected speaking, eating, swallowing, drinking, and breathing.



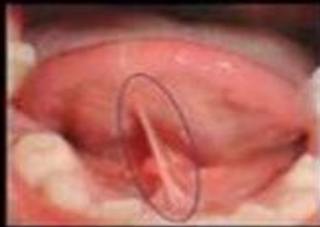Oral examination

- ❖ Presenting heart shape when tongue raised
- ❖ Presenting V-shape notch
- ❖ Inability to extend and elevate tongue
- ❖ Tongue tip curves down when extends

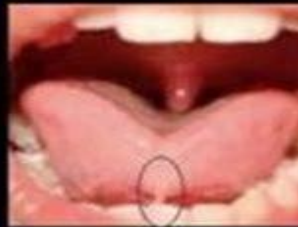Take the tongue tie test.



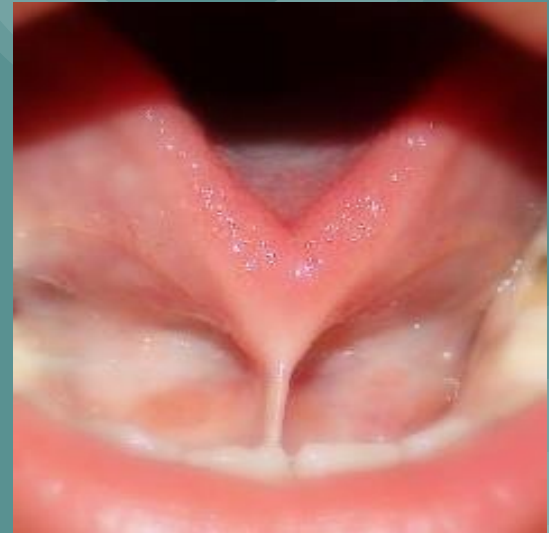Normal



Moderate

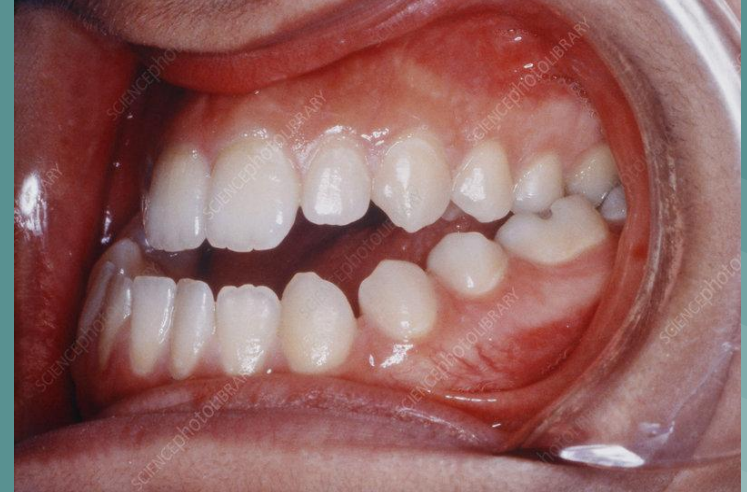
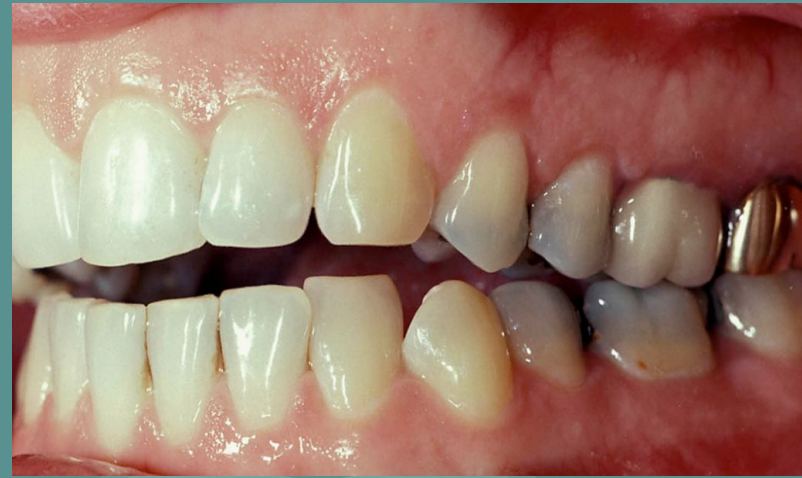
Severe



Other effects:

- ❖ Impede the tongue tip contacts the anterior palate which can be hampered a person progress to an adult-like swallow, and result in an open bite.
- ❖ It might also result in mandibular prognathism when the tongue exaggeratedly push the anterior portion of the mandible.



treatments:

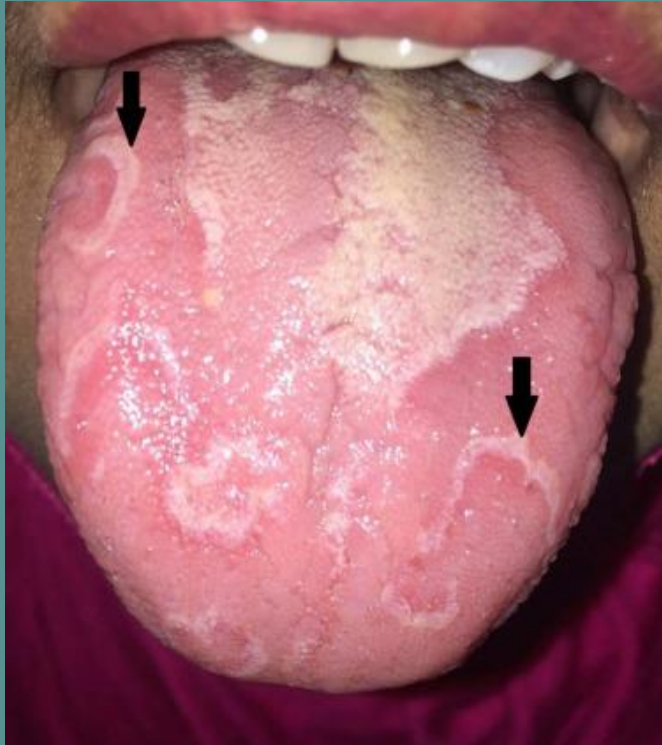Surgical:

- ❖ Three common modalities: Frenotomy, frenulectomy, and frenuloplasty.
- ❖ These surgicals involved cutting the lingual frenulum, rearranging tissues, or adding grafts into incisions.

Nonsurgical:

- ❖ Speech therapy, lactation interventions, and observation to determine whether surgical treatments still needed.

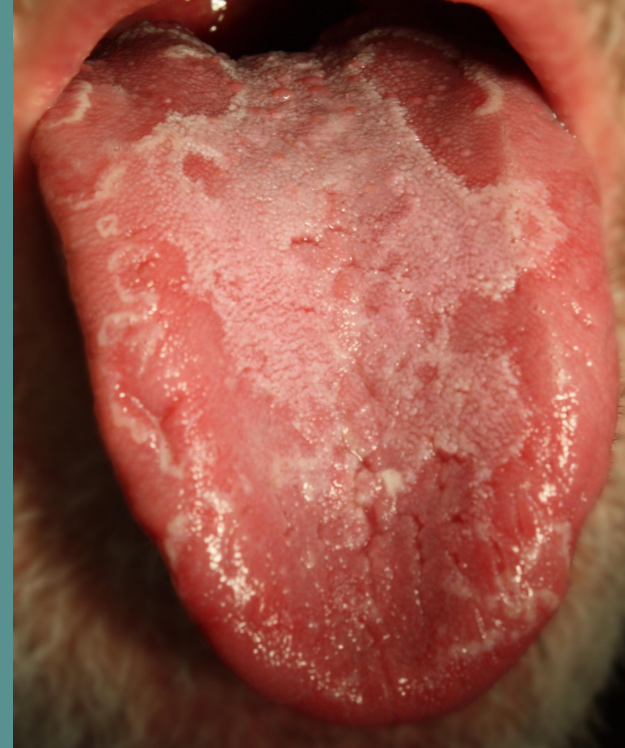Geographic Tongue



By Peiqiong Li

What is geographic tongue?

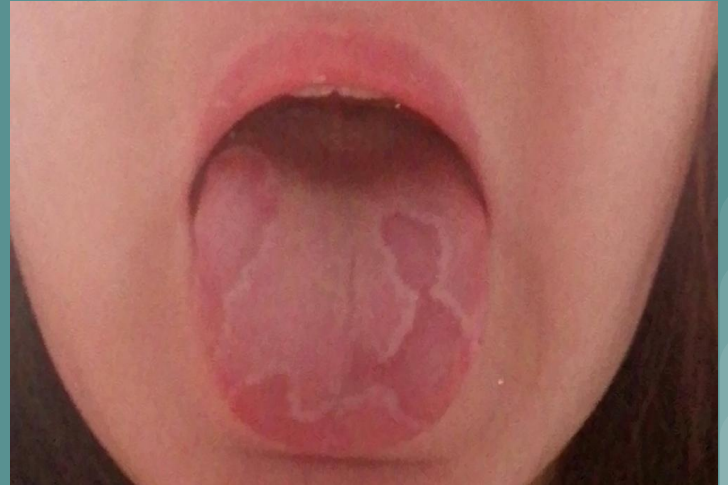- ❖ Smooth and red patches surround by white borders
- ❖ There's no papillae appear on the dorsal surface of the tongue on red area
- ❖ Appears in all ages, more common in young adults
- ❖ Not harmful, not contagious, and will not have long term health problems
- ❖ Most people have no symptom, but some people have burning or stinging sensation



Who is affected?

Doctors not sure what caused the geographic tongue, but there are some related conditions increase the chance to have it:

- ❖ Inherited from parents
- ❖ psoriasis, inflammatory on skin
- ❖ reactive arthritis
- ❖ hormonal surge, if women are taking birth control pills
- ❖ Vitamins deficiency: lack of zinc, iron, folic acid, and vitamins B6,B12.

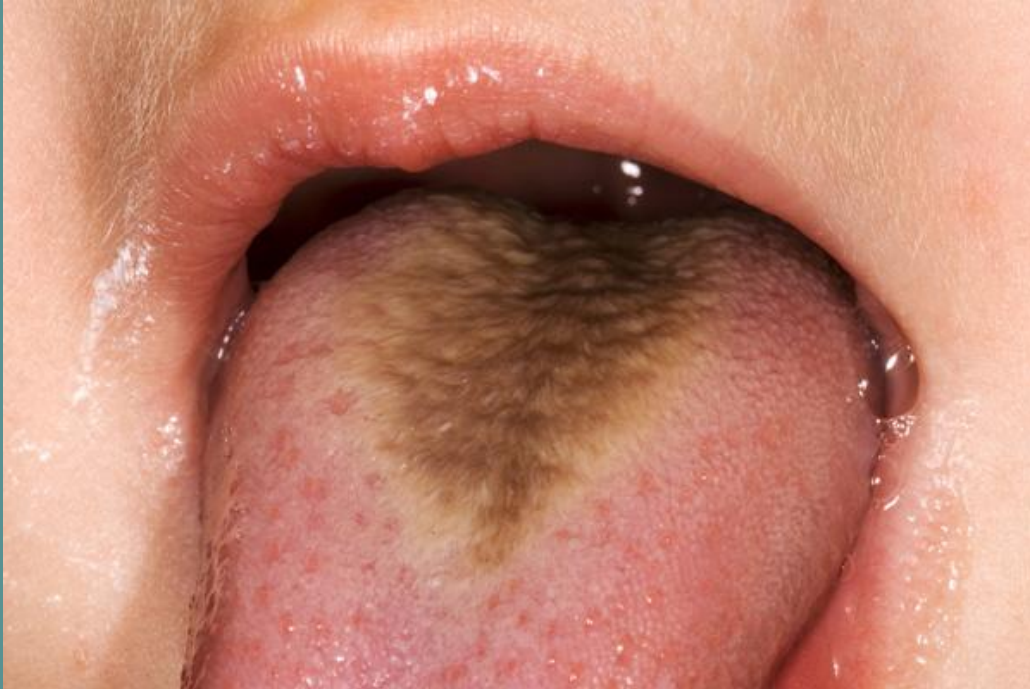

Treatment:

- ❖ Usually is not necessary, because symptoms will come and go. It just looks weird.
- ❖ There is no way for prevention.
- ❖ Go to see your doctor or dentist if the lesions did not resolve within 10 days.



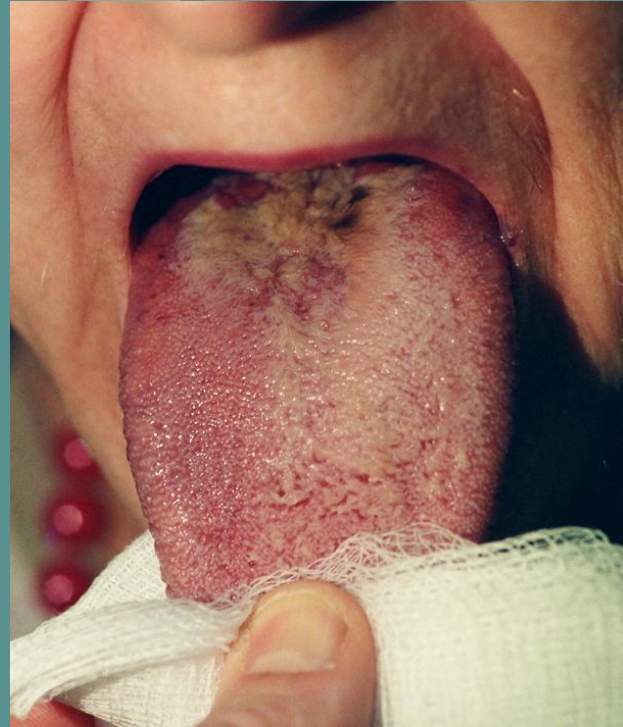
Black Hairy Tongue



By Peiqiong Li

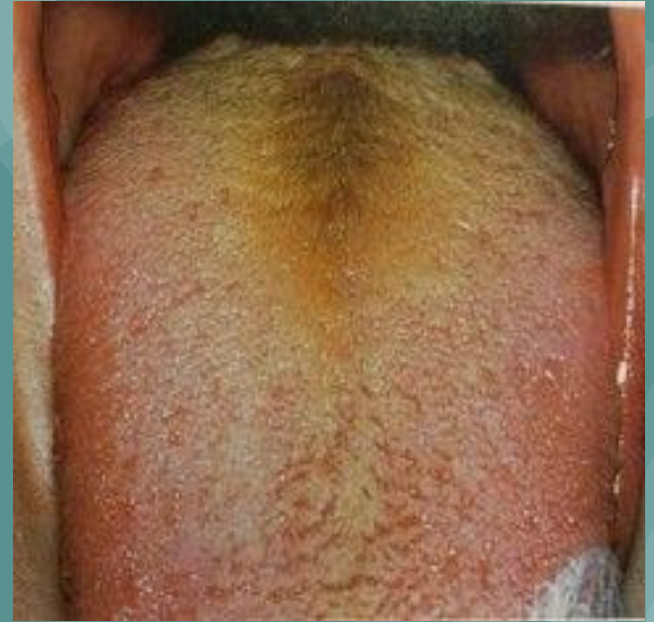What is Black Hairy Tongue?

- ❖ Overgrowth of dead skin cells that extend the length of the papillae (taste buds), give them a furry look, and did not shed the dead skins normally.
- ❖ Temporary, harmless condition, will not cause health problem.
- ❖ Painless.



Signs and Symptoms

- ❖ Color may be black, brown, tan, green or yellow, it depends on what food patients eat, or whether patients are tobacco users or not.
- ❖ Halitosis: bad breath, long papillae collect bacteria or food debris easily.
- ❖ Altered tastes or metallic tastes



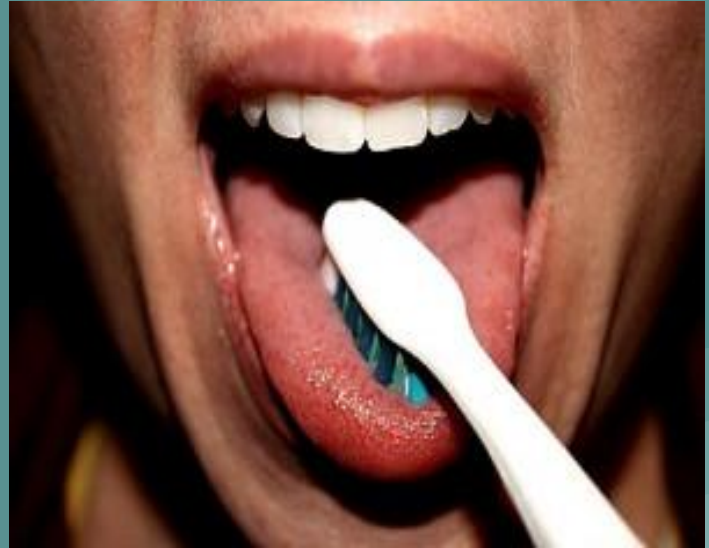Possible Causes

- ❖ Poor oral hygiene
- ❖ Medications use
- ❖ xerostomia(dry mouth)
- ❖ Drinking excessive coffee or tea
- ❖ Smoking
- ❖ Eating soft diets that couldn't help to scrape the dead skin cell
- ❖ Using mouthwash that contain irritating oxidizing agents, such as peroxide



Treatment

- ❖ Brush your tongue while you brush your teeth twice a day.
- ❖ Go to see a doctor when black hairy tongue constantly emerge although you brush it.



Thank You

