



Case Study #1

BY: Minna Harbater


Patient Demographics

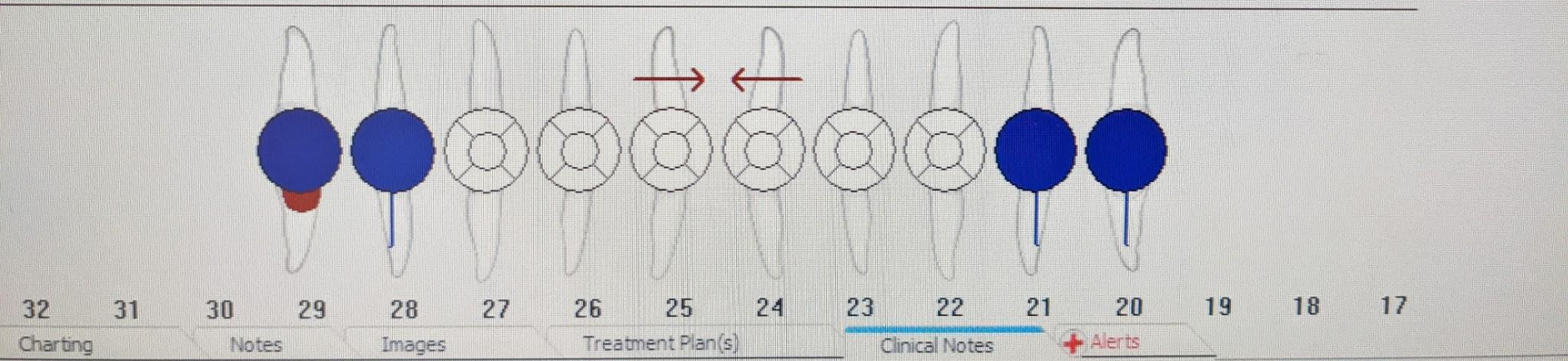
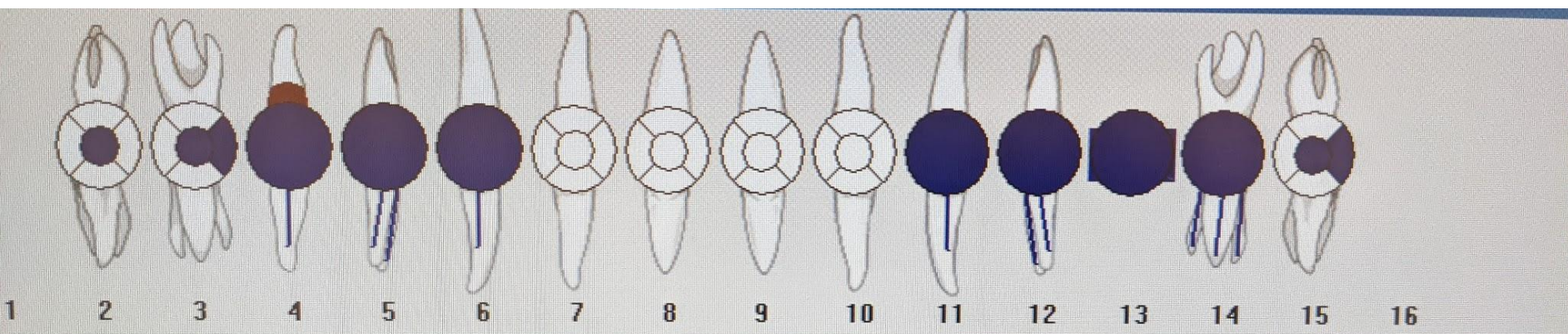
- Name: S.H
 - 79 year old caucasian female
 - Chief complaint: Patient is overdue for a cleaning due to Covid
 - Patient uses a manual toothbrush with colgate toothpaste twice a day and uses floss threader three times a week and Listerine twice a day.
- 

Medical History

- Vitals: first reading- 166/93; pulse:90. Second reading-158/90; pulse: 90.
 - Covid status: tested negative 9/20, negative covid pre-screening was negative.
 - Last physical was done in 8/2020.
 - Patient needs to bring a medical clearance from pcp for next visit, due to hypertension.
 - Patient is currently being treated by Dr Stein in Columbia hospital for a tumor on the her kidney. Patient finished 12 weeks of chemo 3 weeks ago.
 - patient taking Carvedilol and Losartan for high blood pressure and Metformin for pre diabetes and eliquis for irregular heartbeat.
 - Patient is taking 3000 mg of vitamin d daily.
 - Patient reports dry mouth occasionally and has had periodontal gum treatment in the past.
 - Last dental cleaning was in 1/2020 and last dental xrays were taken in 5/2019.
 - ASA 2
- 


Assessments

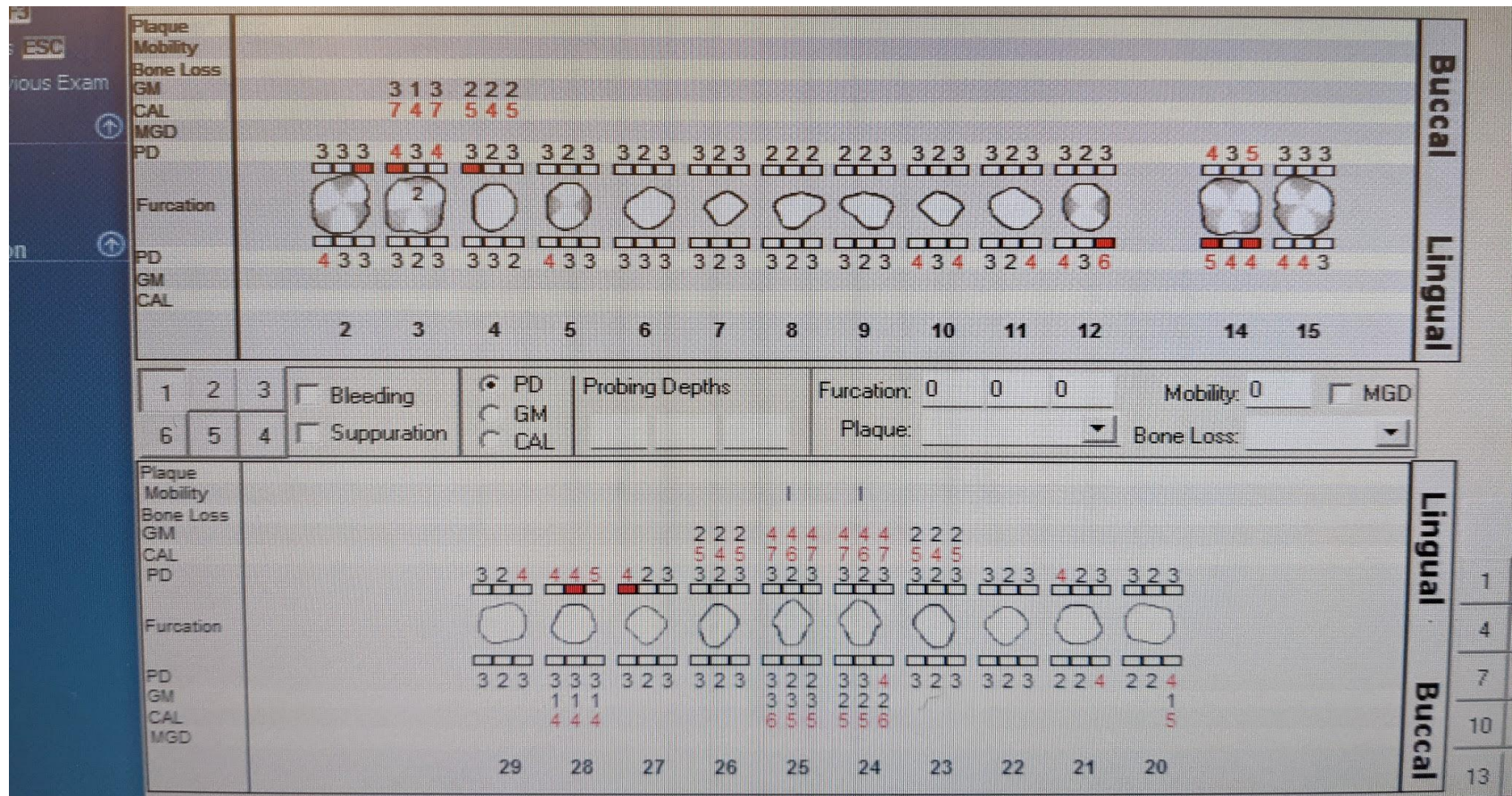
- Extra oral: patient had enlarged submandibular salivary glands.
 - Intra oral: patient had a healing herpetic lesion on left vermilion border, patient had a coated tongue and there was lip bite on the mandibular labial mucosa.
 - Gingival statement: Gingiva was pink, slightly soft, generalized inflammation with blunted papilla.
 - Dental charting: Patient is missing #31,30,19, and 18, there is attrition present on mandibular anteriors.
 - Class I occlusion 5% overbite and 2 mm overjet.
 - Furcations present on #2 and 14.
 - Found suspicious decay on #4 and 29 buccal.
- 



Dental Charting

Assessments

- Perio charting: readings of 4 and 5 mm on the posteriors and recession of 2 and 3 mm the mandibular anteriors and 1 and 2 mm on the posteriors. Minimal generalized bleeding upon probing.
 - Calculus detection: found supragingival calculus on the mandibular anteriors and subgingival calculus on the maxillary posteriors.
 - Classified patient as a medium case value with heavy staining on the lingual.
 - Classified patient as Perio case stage III grade B due to the amount of bone loss present on previous x rays and due to patients age and diabetes
- 



Perio Charting

Cancer Patients

- Cancer affects one in 3 in the U.S
- Cancer begins when there is a change in the process of cell division and life, where old or abnormal cells don't die and they begin to overcrowd the healthy cells.
- Cancer can affect any part of the body. There are two types that affect the body Hematologic which is cancer of the blood cells and solid tumor cancers which is cancer of the organs and tissues.
- Cancer can spread from the primary site to the rest of the body, when it spreads it is called metastasis.
- Some symptoms of cancer include, tiredness, weight loss, swellings or lumps, unknown pain.
- Survival rate will depend on the type of cancer and the stage it was found. There is not one cure for cancer
- Remission is when the body responds to the treatment and complete remission means they cant find cancer cells with testing,



Dental considerations for cancer patients

- Patients undergoing cancer treatment need to make sure to keep excellent oral health
- Patients should be told to do daily self exams to spot any infections or adverse effects from the treatment
- Head and neck exams should be well documented at the hygiene appointment
- It is crucial to maintain regular hygiene appointments to assist with oral health
- Patients should be told that continuing oral health care will benefit the general health during the fight against cancer.



Hypertension

- blood pressure is the force of blood pressing against the artery walls, when the force is too strong, a person has high blood pressure.
- High blood pressure cannot be cured but can be controlled with exercise and diet or medication
- The top number is the force of your blood from the heart into the vessels, known as the systolic and the second number is when the heart is at rest.
- If the blood pressure is consistently high then there is too much pressure on the heart and blood vessels.
- High blood pressure can have damaging effects on the heart and kidneys
- Known as the “silent killer”, since you can feel fine and don't have any symptoms



Blood Pressure Categories

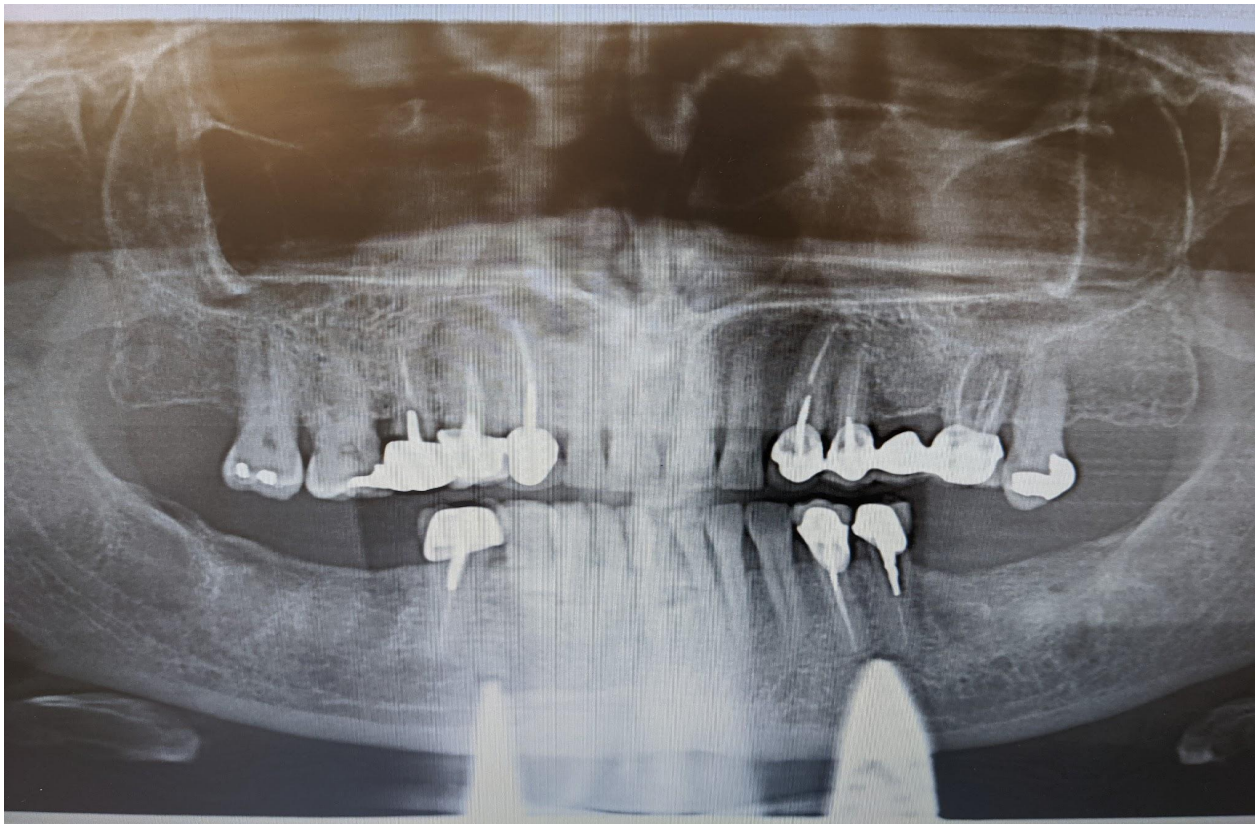


BLOOD PRESSURE CATEGORY	SYSTOLIC mm Hg (upper number)		DIASTOLIC mm Hg (lower number)
NORMAL	LESS THAN 120	and	LESS THAN 80
ELEVATED	120 – 129	and	LESS THAN 80
HIGH BLOOD PRESSURE (HYPERTENSION) STAGE 1	130 – 139	or	80 – 89
HIGH BLOOD PRESSURE (HYPERTENSION) STAGE 2	140 OR HIGHER	or	90 OR HIGHER
HYPERTENSIVE CRISIS (consult your doctor immediately)	HIGHER THAN 180	and/or	HIGHER THAN 120

Dental considerations for hypertension


- Patients with uncontrolled hypertension should have a consultation with the patients provider before getting treated
- Topical vasoconstrictors are not recommended and Intravascular injections should be avoided
- Medications used to treat hypertension can cause xerostomia, burning mouth and gingival bleeding
- Patients taking calcium channel blockers can present with gingival hyperplasia





Radiographs: indicate generalized 50% bone loss present.

Dental care plan

- On the first visit, Patient had a plaque index score of 1.3 generally around the gingival margins, demonstrated the modified bass method and had the patient practice herself in the mirror. Hand scaled quadrants I and IV.
 - On the second visit, Patient had a plaque index of .5, demonstrated flossing with floss thread. Hand scaled quadrants II and III, engaged polished with medium grit and applied 5% fluoride varnish treatment. Patient was given post instructions for the varnish.
- 

Referral

- Gave patient referral to provide to her general dentist to suspicious decay on #29B and recurrent decay on #4F
- Recommend patient return for a hygiene appointment in three months time due to the stage of perio disease.
- Recommend the patient purchase an powered toothbrush to aid in proper brushing technique and continue brushing, flossing, and using Listerine twice a day



Reflection

After working with a patient who unfortunately suffered from hypertension and having chemotherapy and eventually having her kidney removed, taught me a lot and gave me a great learning experience. The patient was happy with her life despite her challenges and was thankful for everything she had. I am very happy with how the treatment was implemented and the patient's investment to continue working on her oral health care. She was very grateful and happy with the visits we spent together. I encouraged to continue with the regular hygiene appointments and daily home care.



Citations

1. Cancer.org. 2021. *Can Cancer Be Cured?*. [online] Available at: <<https://www.cancer.org/treatment/understanding-your-diagnosis/can-cancer-be-cured.html>> [Accessed 10 May 2021].
2. Gurenlian, RDH, Ph.D., J., 2015. Maintaining Oral Health During Cancer Treatment. *Oral health network for professional education and development*.
3. Dentalcare.com. 2021. *Hypertension | Management of Patients with Chronic Diseases | CE Course | dentalcare.com*. [online] Available at: <<https://www.dentalcare.com/en-us/professional-education/ce-courses/ce567/hypertension>> [Accessed 10 May 2021].

