

# Clinical Case Study II

By Kichelle Williamson

New York City College of Technology

## Patient Information

27 year old Asian female. Frequent marijuana smoker. Occasional drinker. Last dental cleaning was in 2021. An FMS was taken at that time. Patient is brushing with a medium manual TB using Colgate TP twice daily. Patient is flossing twice daily. Patient is not using a tongue scraper. Patient is rinsing with Listerine twice daily.

## Chief complaint

Patient stated that she needs a cleaning and that her gums were swollen a couple months ago on the upper right side.

## Medical History

Last physical examination was 10/6/2021.

Vital signs: BP: 116/79 Pulse: 90.

Patient is taking birth control Larin Fe 10mg once daily.

Patient has seasonal allergies.

No other systemic conditions were reported.

ASA 2.

## Clinical Findings

**EO:** Crepitus of the TMJ on the right side-asymptomatic.

**IO:** Bilateral linea alba. Scalloped tongue. Small palatal torus

Gingiva appears pink, GM slightly inflamed, near CEJ with localized areas of recession (perio chart included), interdental papillae are bulbous, soft, smooth, and moderate BOP with no exudate.

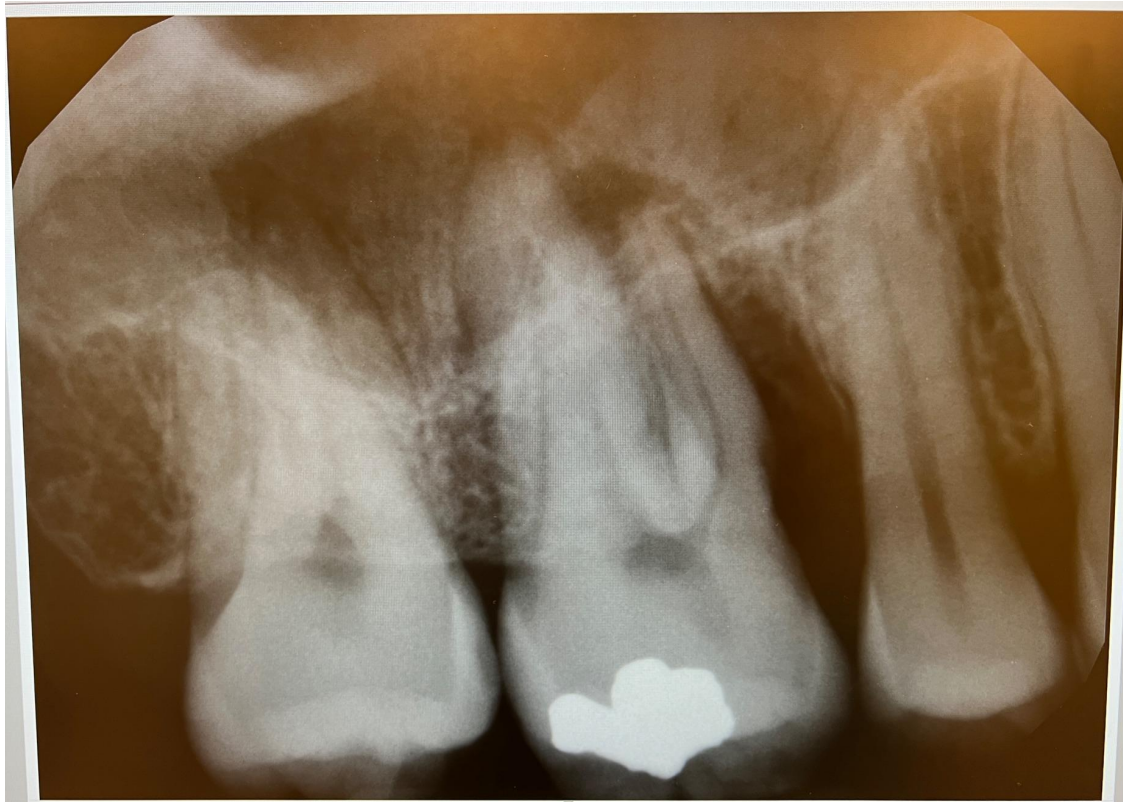
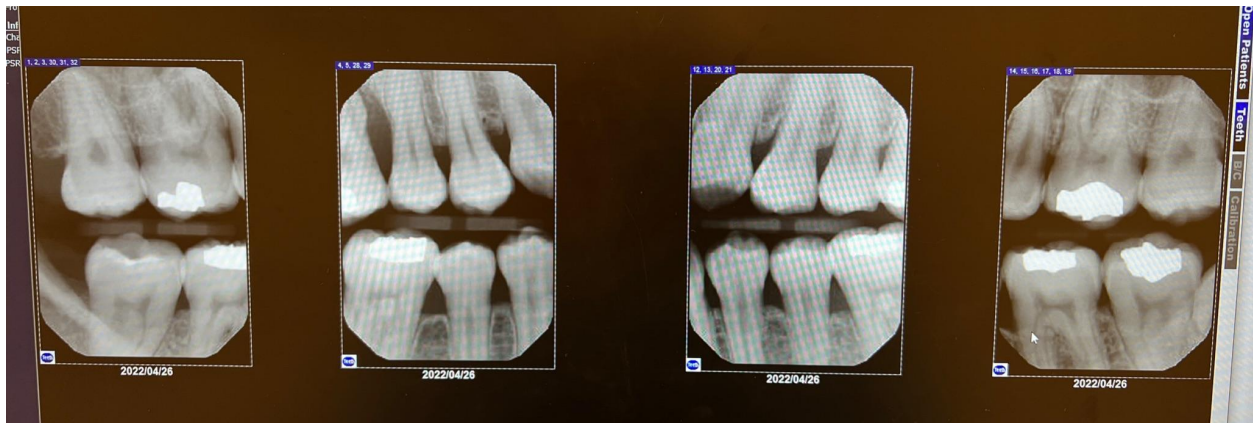Generalized 1-6mm probing depths with localized 10mm on #3-MB, 8mm on #3-ML, and 11mm on #4-MB. Mild inflammation of GM.

Bilateral Class III occlusion. Cross bite on right side. Overjet: 3mm. Overbite: Edge to edge bite on anteriors.

Abfraction present on tooth #5.

Patients case value is medium due to subgingival calculus.

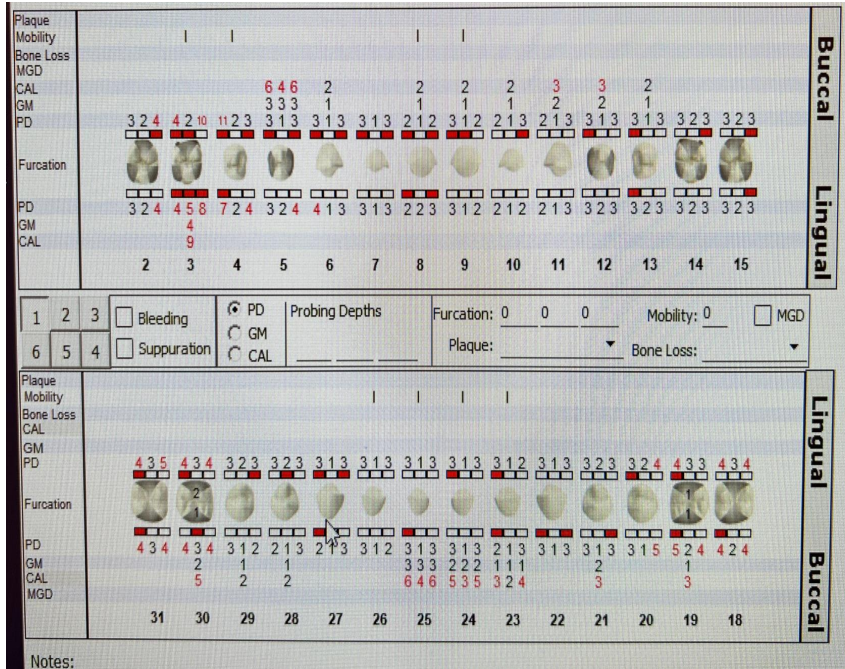
## Radiographic Findings



4 Horizontal Bitewings and 1 Periapical were taken using 7 mA and 70 kVp. No carious lesions evident. Radiolucency present around teeth #2 and 3. Generalized 15% horizontal bone loss present with localized vertical bone loss present on tooth #3-M.

### Periodontal staging and grading

Upon evaluation of radiographs the patient was classified as periodontitis Stage III/ Grade C.



## Treatment Plan

Due to time constraints, this patient was completed in one visit.

Visit 1: Reviewed medical history, completed all assessments, received consent for TX., PI/OHI-Flossing, Modified Bass, and Listerine Total.

Complete debridement of all quadrants using ultrasonics and hand scaling with the exception of teeth #2,3, and 4. Engine polished and administered sodium fluoride varnish 5% Post-op instructions were given to the patient.

## Referral and Recommendations

An adult referral was given to patient for periodontal and orthodontic evaluation, also for evaluation of defective restoration.

Patient was recommended to brush twice daily, floss daily, and rinse with Listerine Total care twice daily.

Patient was informed of periodontal findings and advised to return in 3 months for recare.