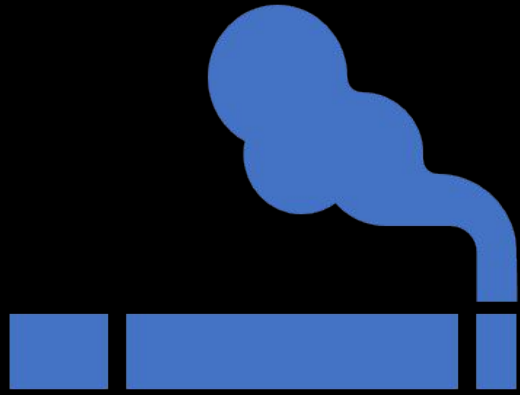

# NICOTINE STOMATITIS

## WHAT IS IT?

---

Common tobacco related type of keratosis that occurs exclusively on the hard palate

---

It is a reaction seen on the roof of the mouth caused by extreme heat

---

Diffusely white with red, punctuate areas which represent the inflammation of the salivary gland duct

---

Not caused by nicotine

---

**Also known as:** smoker's palate, smoker's keratosis, nicotinic stomatitis, stomatitis nicotina

## CAUSES

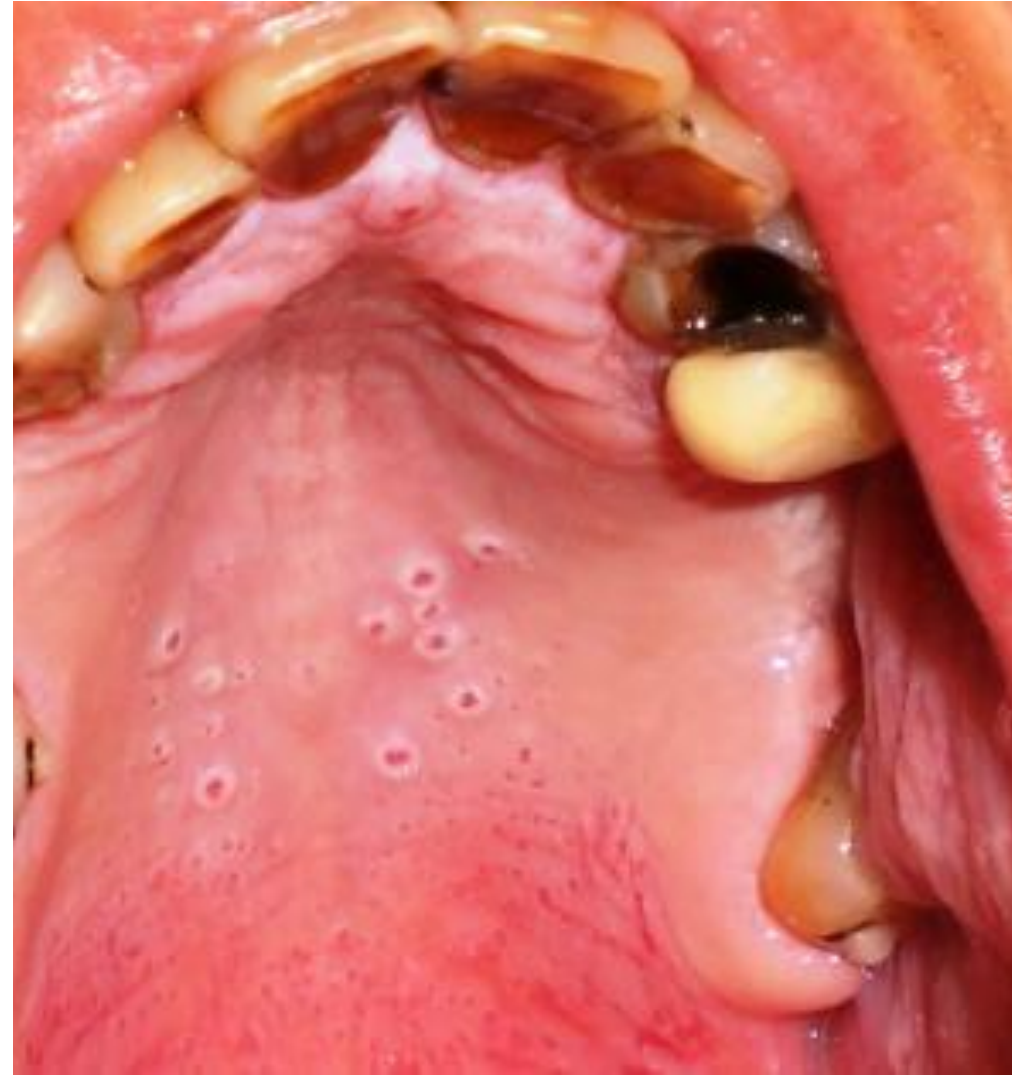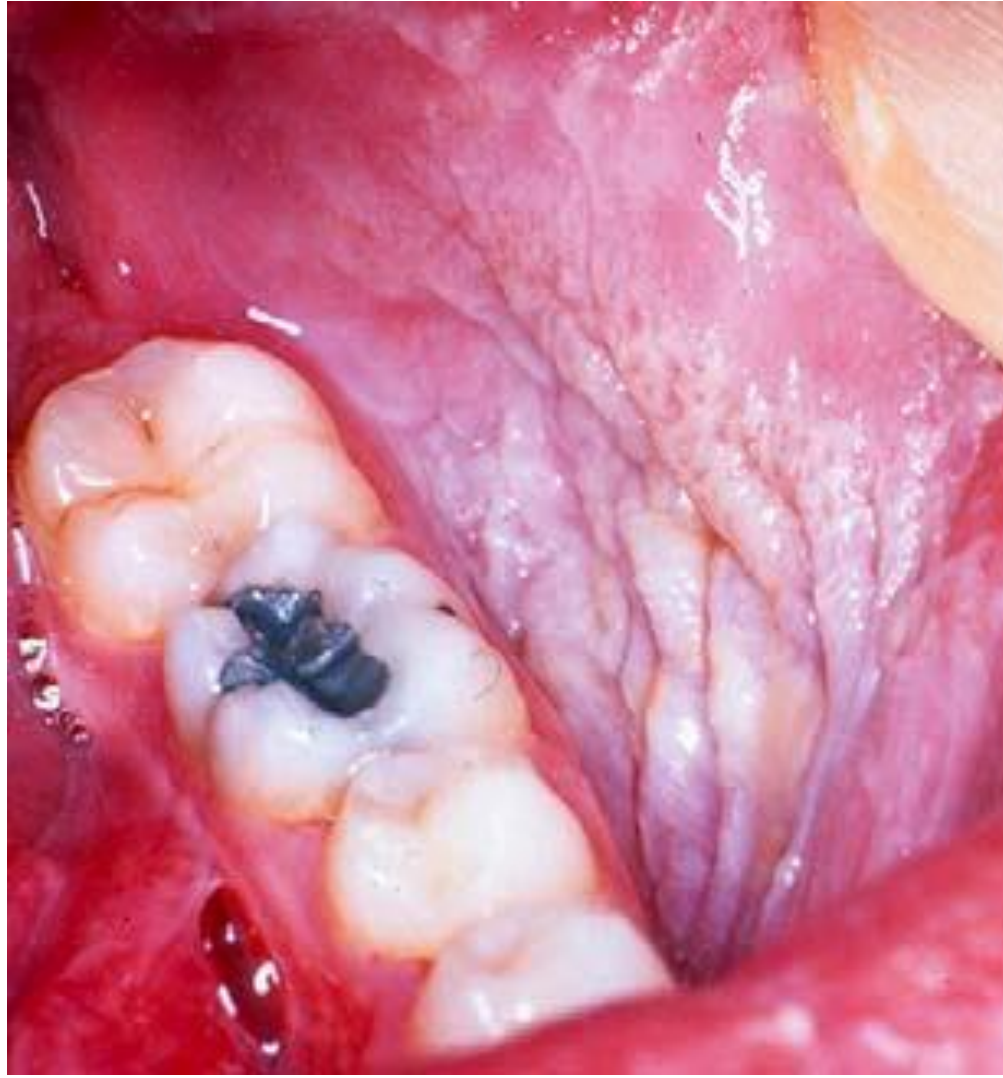
most commonly causes are from smoking

to be chemical or thermally induced  
keratosis

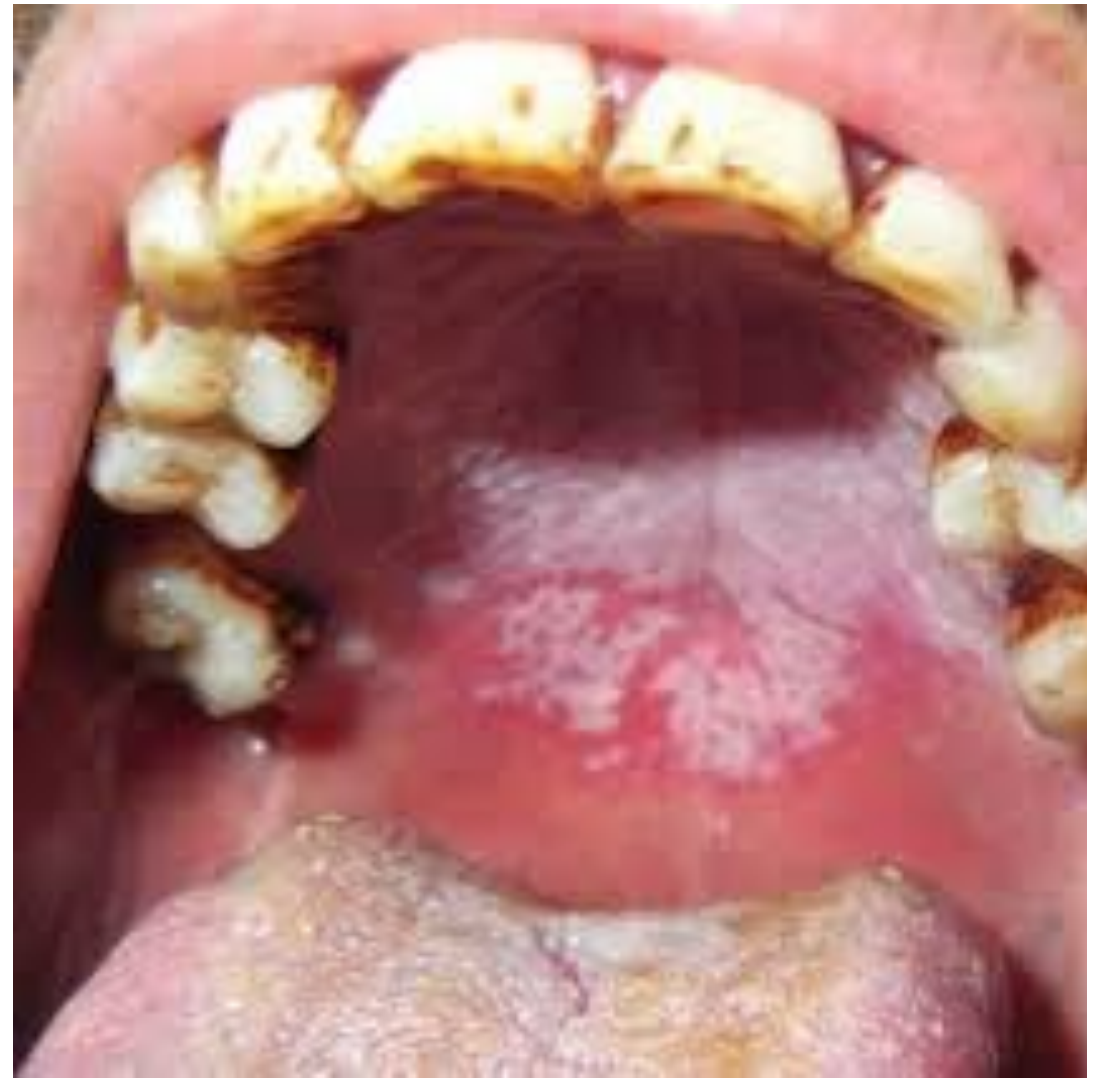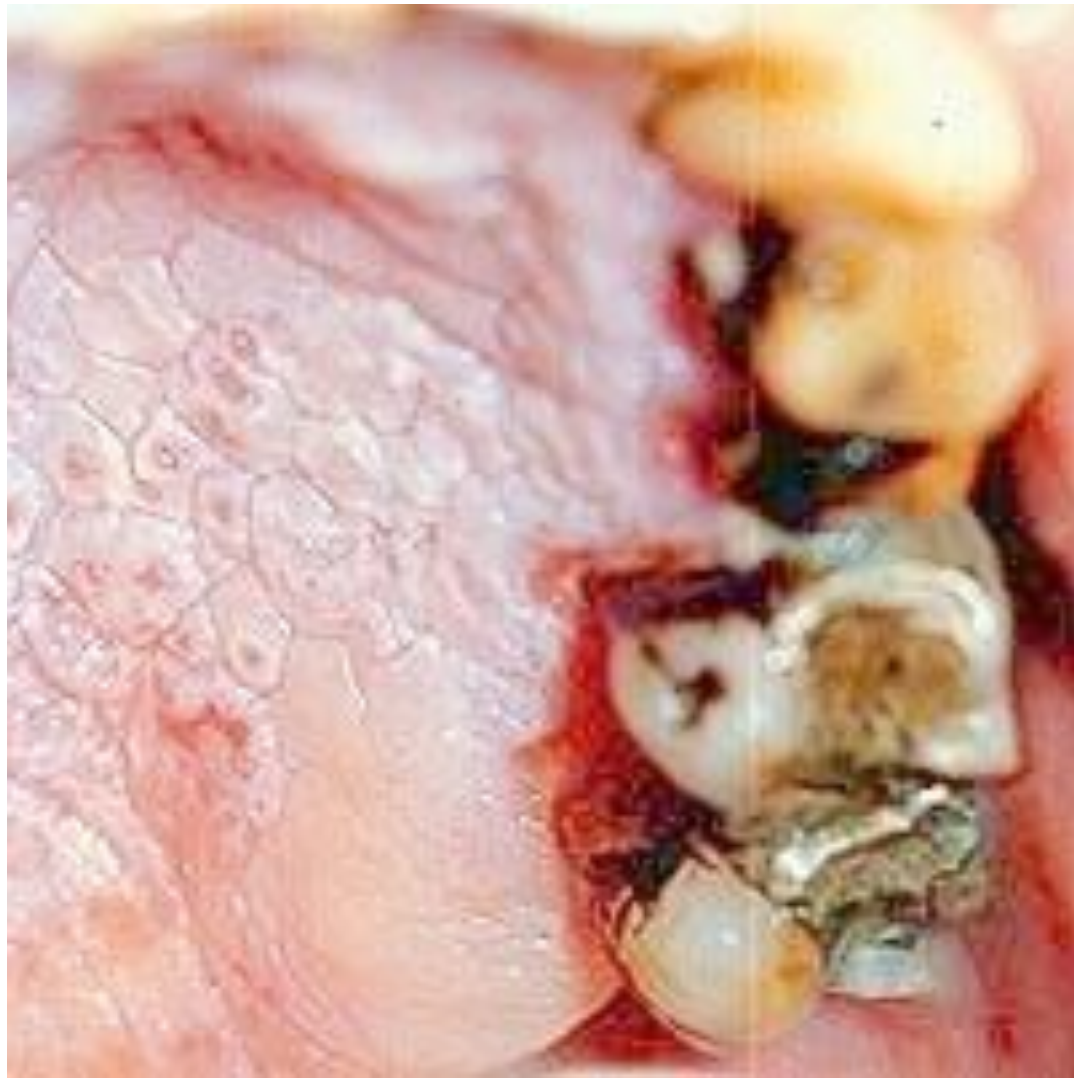chemicals in tobacco may act as irritants  
in this condition

Chronic heat exposure is also responsible

Pipe smoking produces more heat on the  
palate than any other forms of smoking.







# TREATMENT OF NICOTINE STOMATITIS



THE ONLY TREATMENT IS TO  
STOP SMOKING.



THE CHANGES THEN  
IMPROVE WITHIN 1-2 WEEKS.

# DENTAL ROLE

Regular examination of the mouth is required because of the risk of oral cancer in smokers.

Any persistent or suspicious areas should be biopsied.