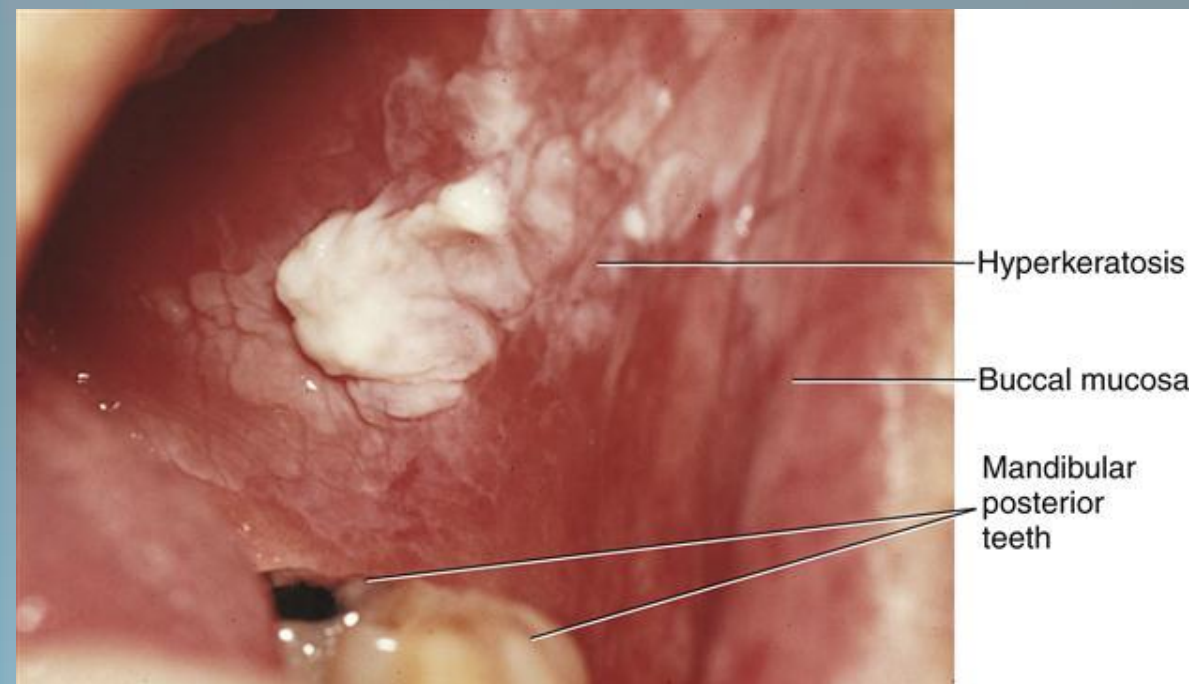
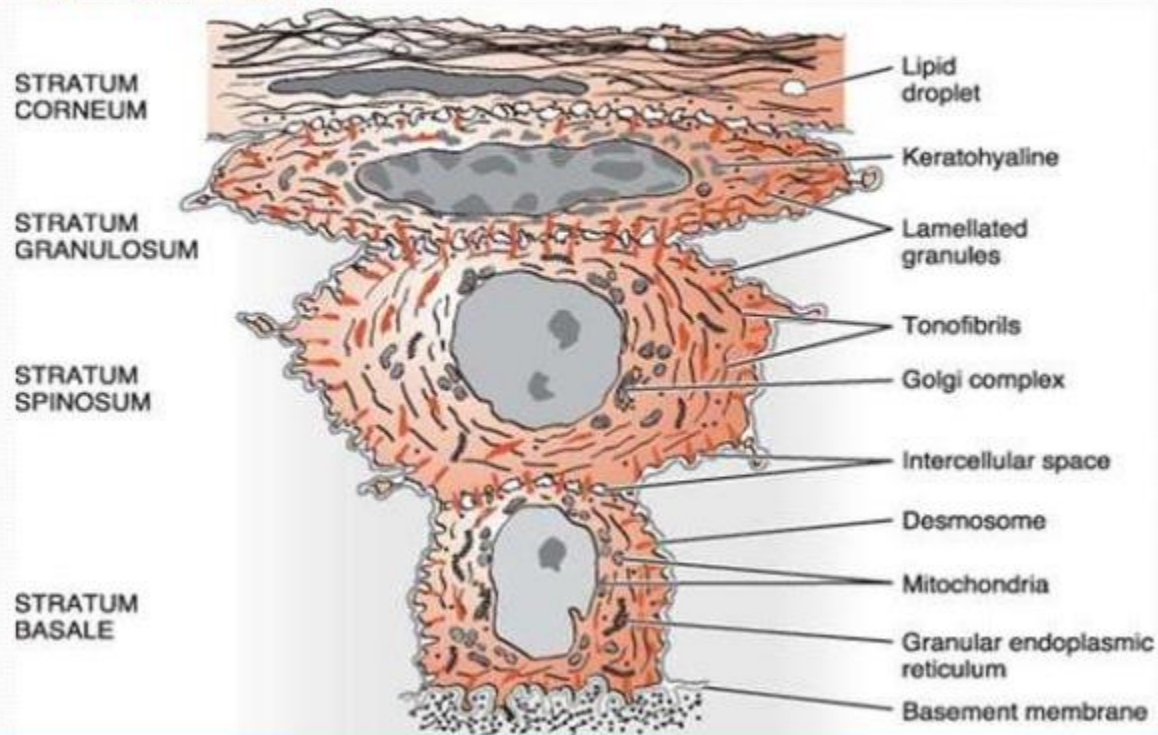
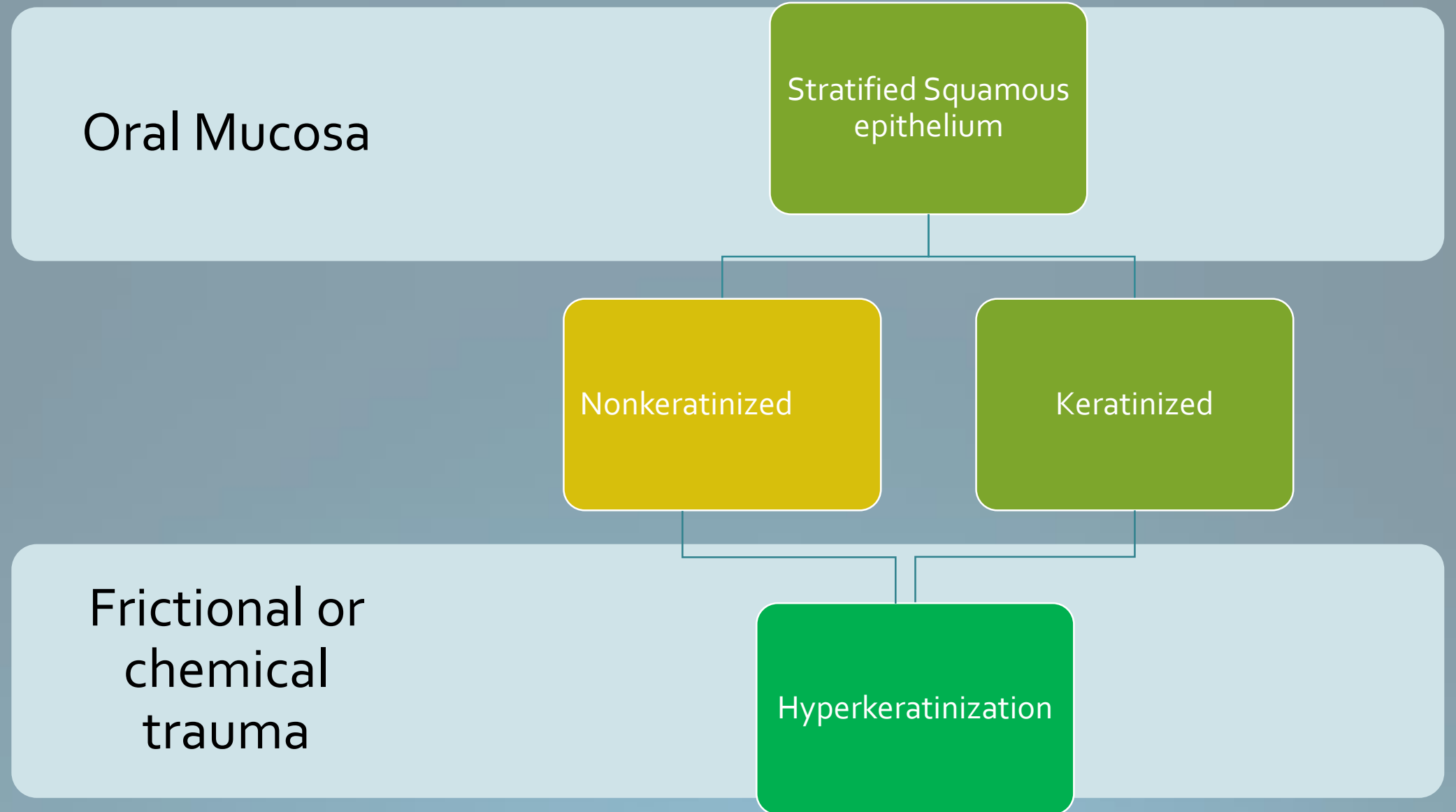


# Hyperkeratinization of the Oral Mucosa

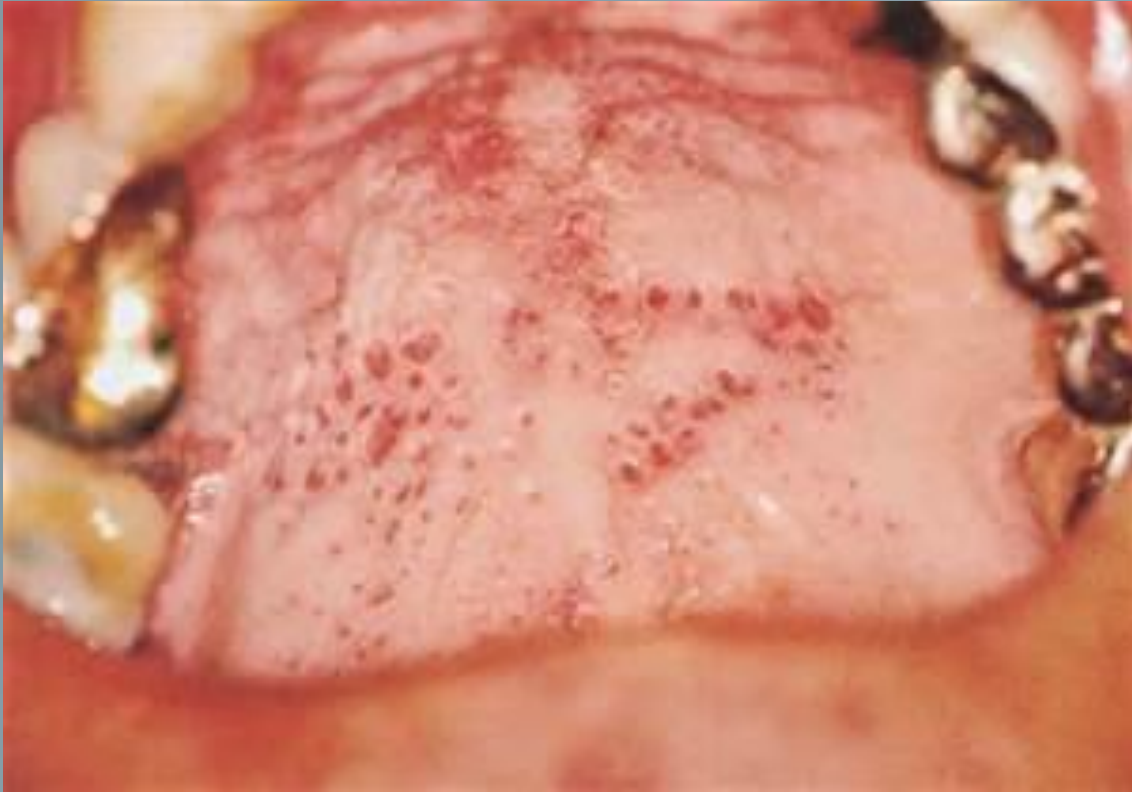## CELL LAYERS OF ORTHOKERATINISED EPITHELIUM



# Hyperkeratinization



# Nicotinic stomatitis



- Known as smoker's palate
- Caused by heat from smoking or hot fluids in the hard palate
- It is asymptomatic
- Red dots are minor salivary glands

# Clinical considerations:

- Hyperkeratinization is mostly occurs on nonkeratinized buccal mucosa epithelium due to excess of keratin, where all the layers of orthokeratinized tissue is present.
- Keratinized tissue can undergo further level of Hyperkeratinization.
- Reversible if the irritant agent is removed.
- If any whitened tissue still present baseline biopsy and microscopic study is recommended.
- Dental Hygienists can perform an Oral cancer screening using fluorescence light.

