



COMMON ORAL DISEASES

By Christina Branco



ORAL HYGIENE

- Oral hygiene is crucial!
- A healthy mouth is a healthy body!
- Dentures and missing teeth are not inevitable!
- You have the tools!



CAVITIES

- Also known as dental caries, tooth decay
- Cause: acids weaken teeth and break down tooth structure
 - Bacterial digestion
 - Foods and beverages

CAVITIES, CONTINUED

Who is affected:

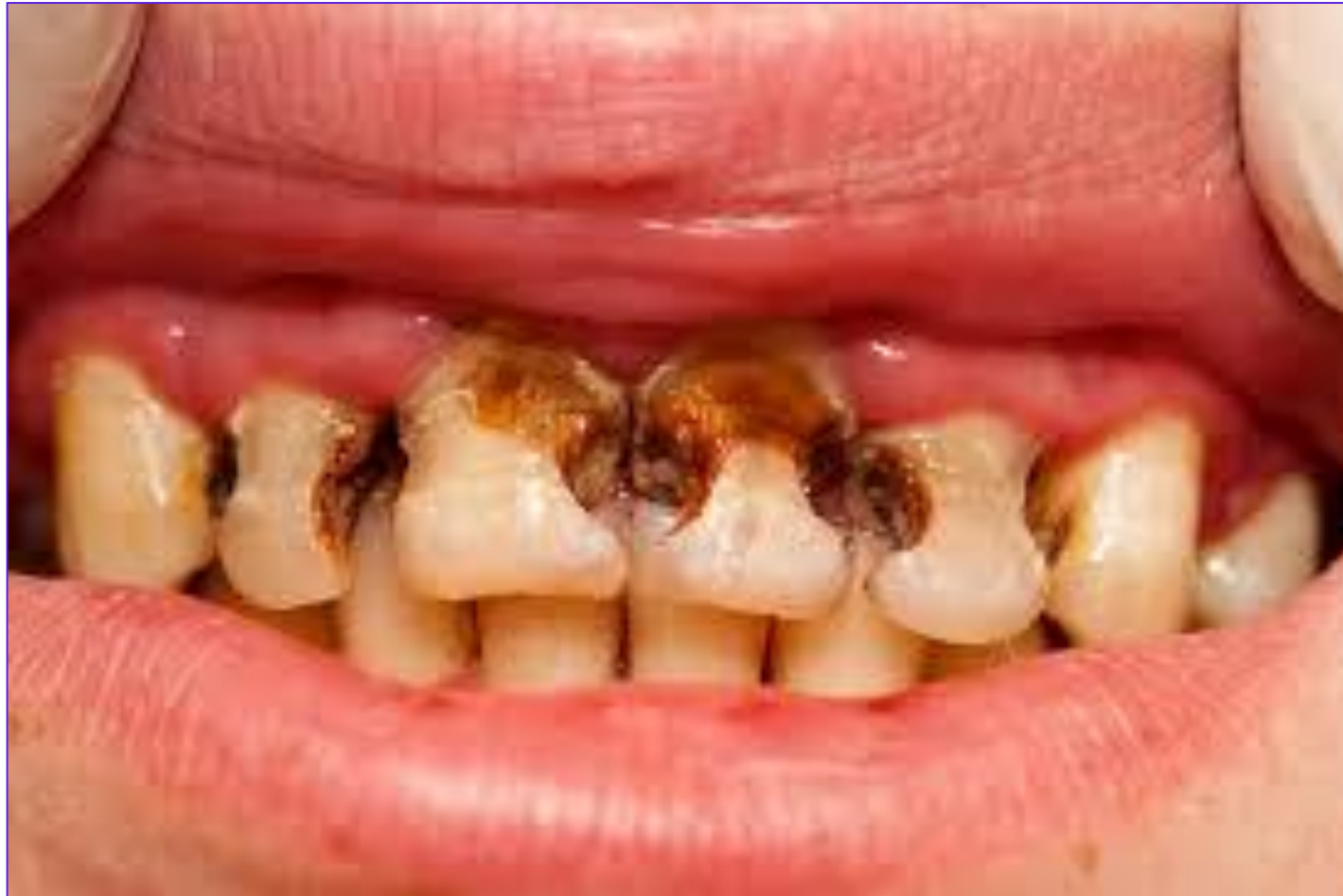- Most common cause of tooth destruction and loss for people under 30

Weinberg, Mea A., et al. *Comprehensive Periodontics the Dental Hygienist*. Pearson, 2015.

- 78% of Americans, at least 1 cavity by 17 years old

Weinberg, Mea A., et al. *Comprehensive Periodontics for the Dental Hygienist*. Pearson, 2015.

CAVITIES ON FRONT TEETH

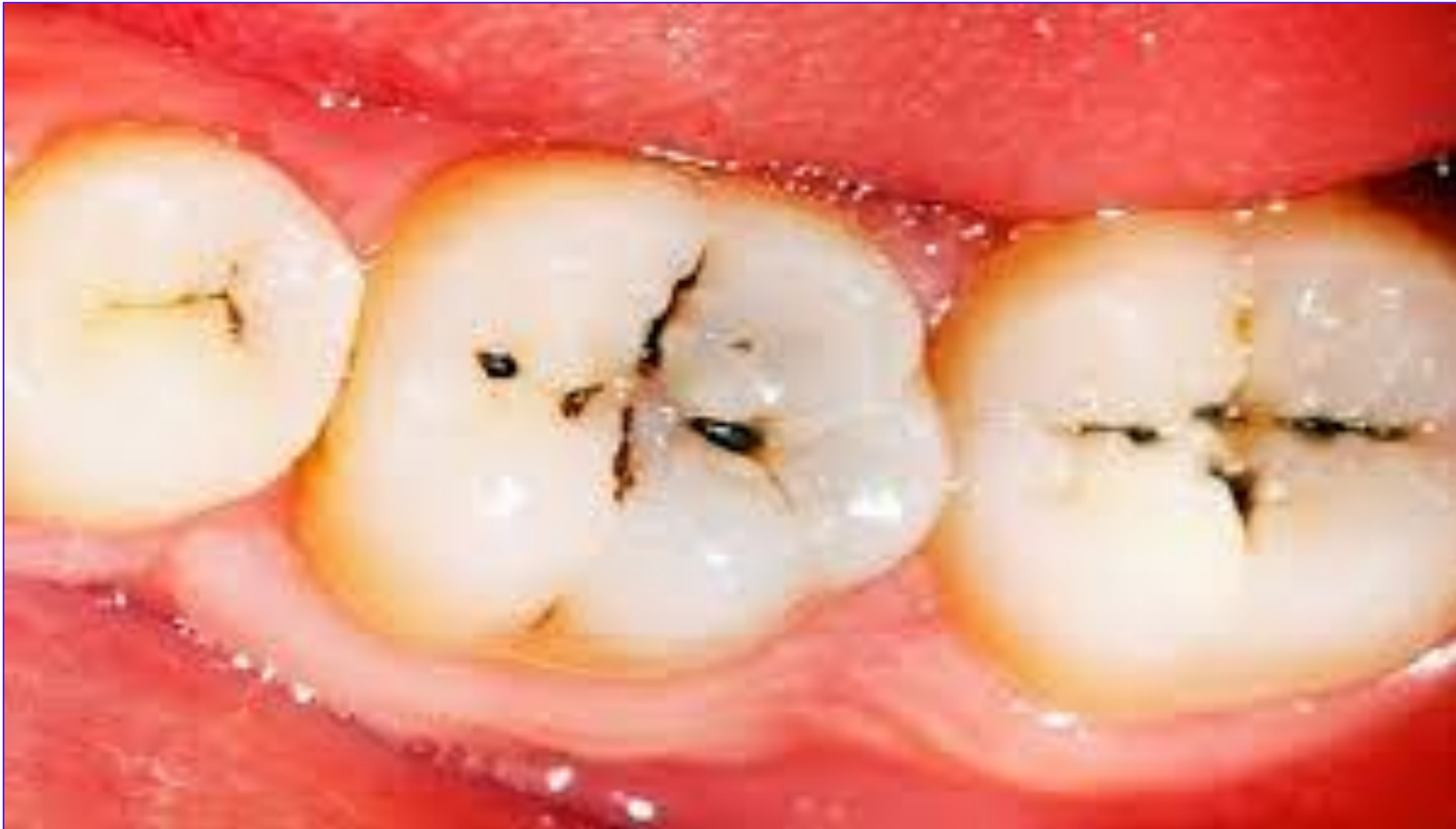



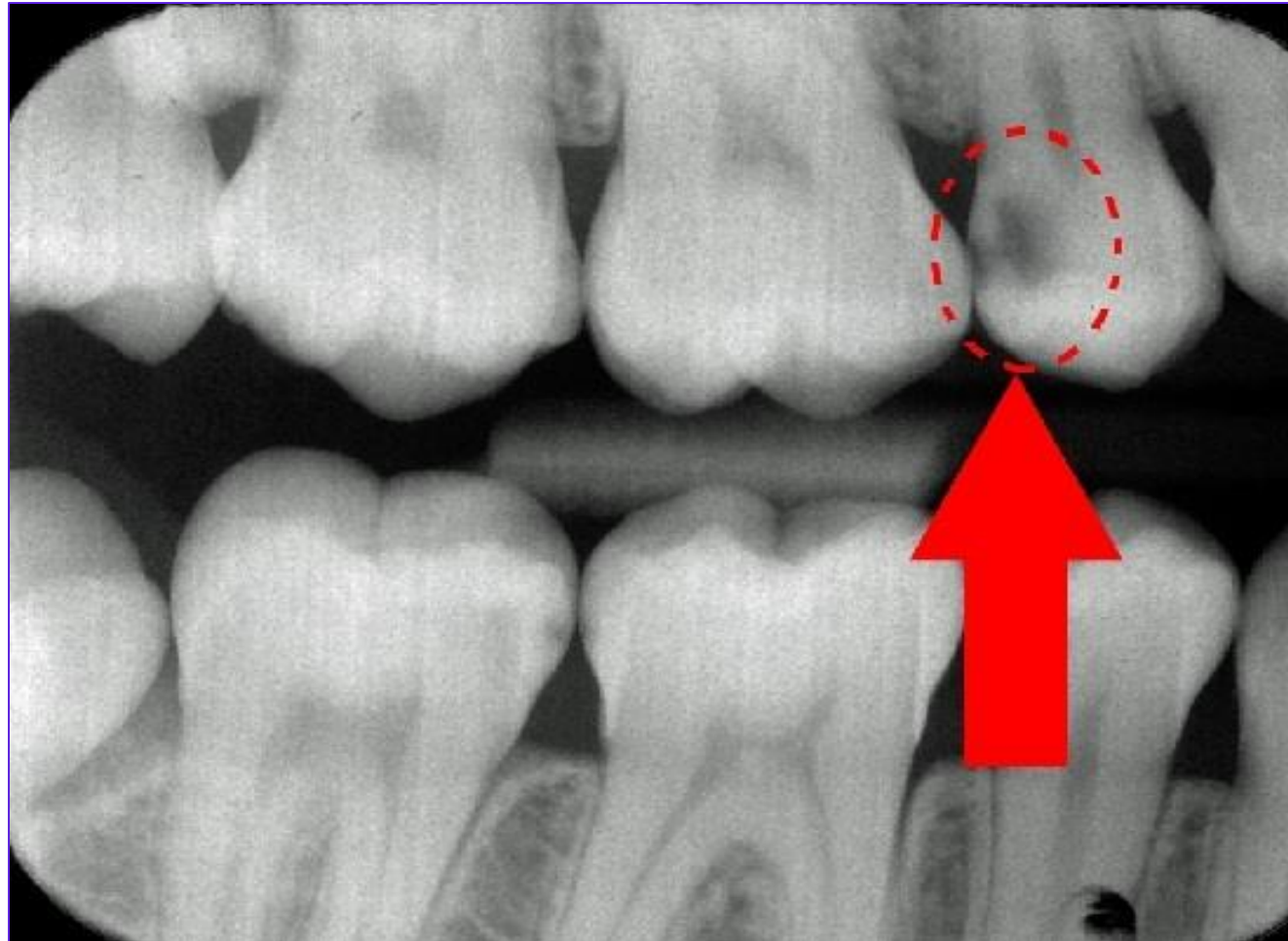
VISUAL SIGNS AND SYMPTOMS

- Color change – bright white spot, brown, black
- Change in translucency – shadow visible during transillumination
 - Transillumination – shining light through a tooth
- Radiographic evidence – dark areas visible on radiographs

COLOR CHANGE DUE TO CAVITIES



CAVITIES ON A RADIOGRAPH





TACTILE SIGNS AND SYMPTOMS

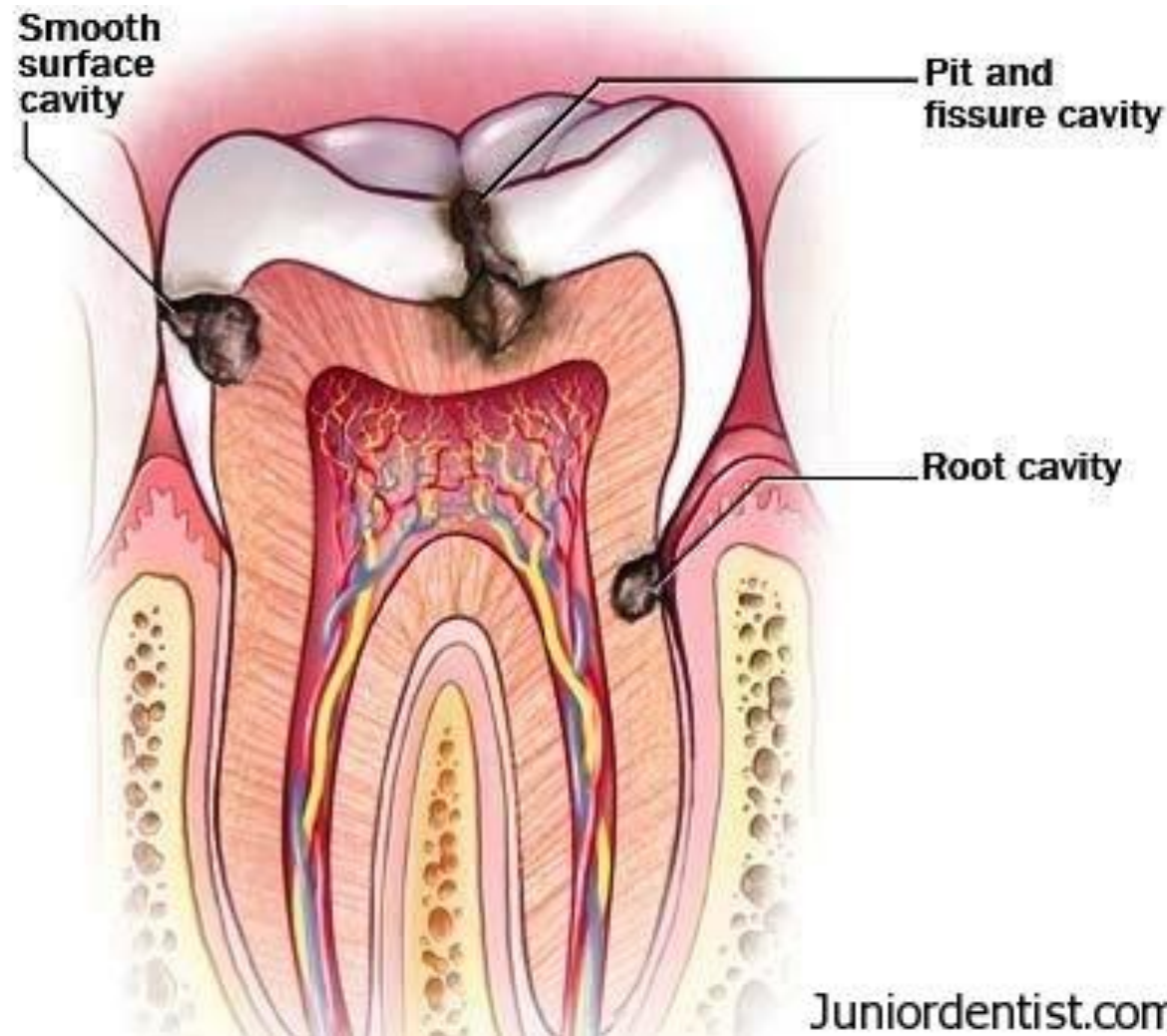
- Sensitivity to temperature
- Sensitivity to sweets
- Pain on biting
- Clinician – use of explorer to feel roughness, sticking



WHERE CAVITIES CAN OCCUR

- Pit and fissure caries
- Smooth surface caries
- Root caries

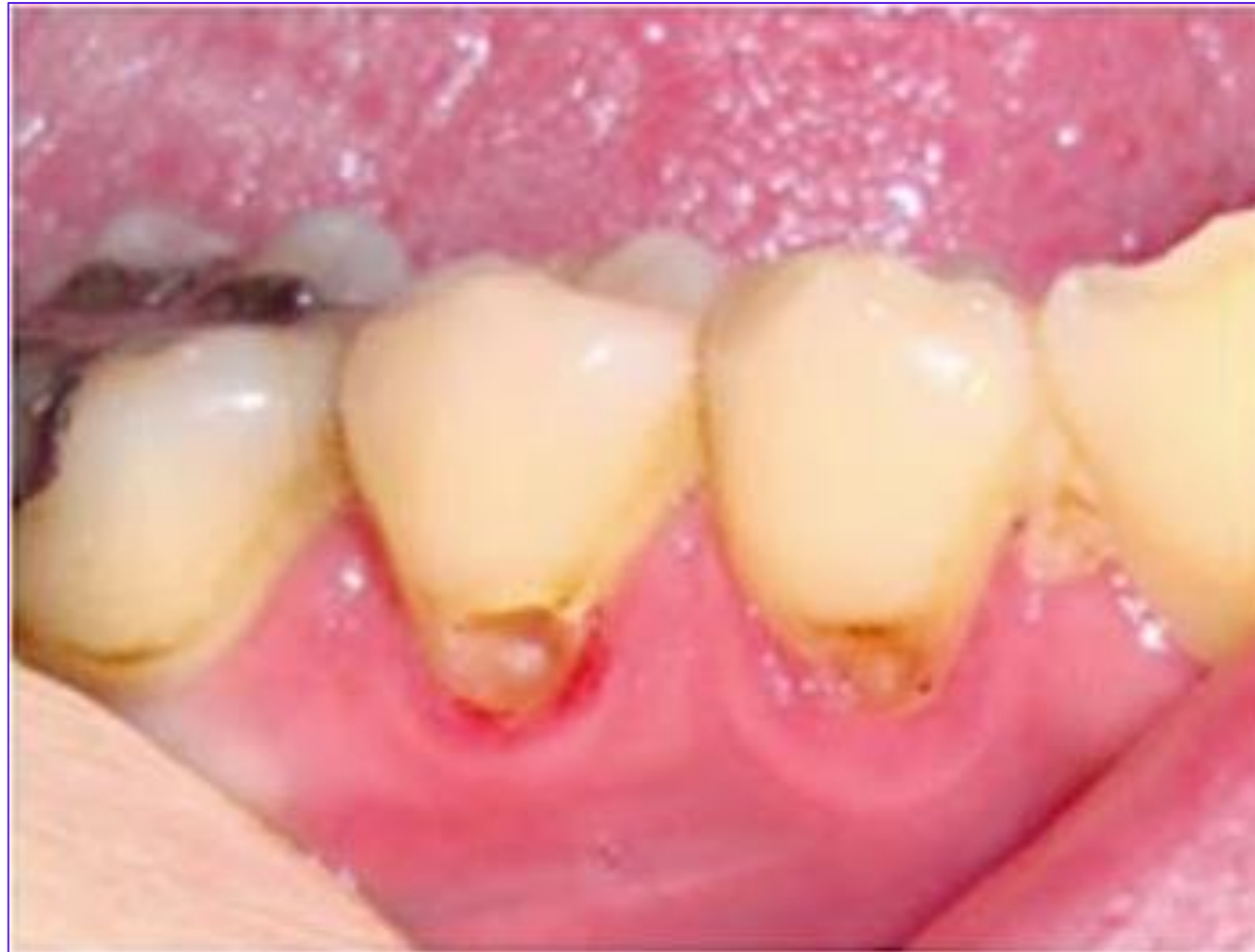POTENTIAL LOCATION OF CAVITIES



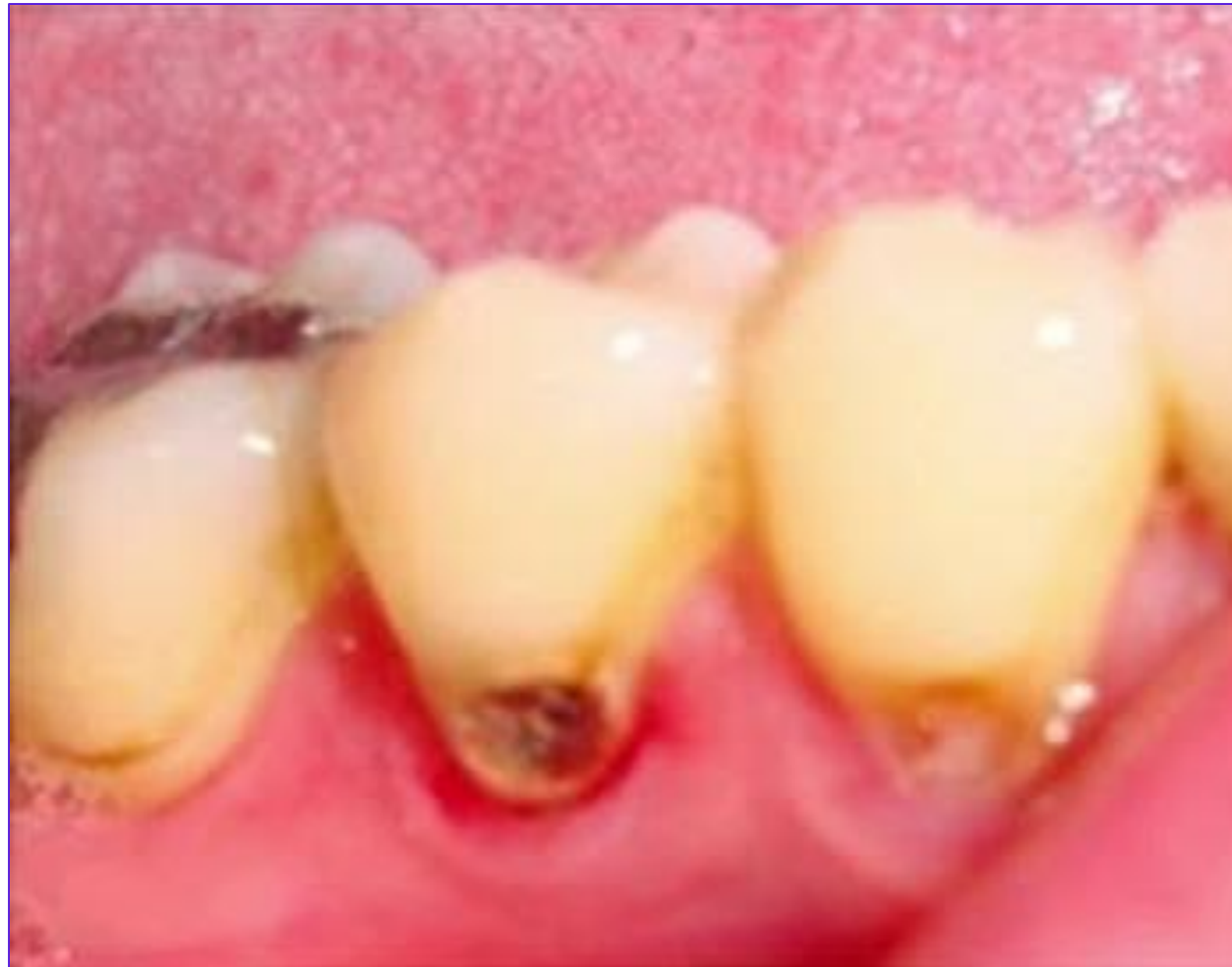TOPICAL TREATMENTS

- MI paste – remineralizes tooth, for small cavities on tooth surface
 - Remineralize – to replace minerals, rebuild tooth structure
- Silver diamine fluoride – for primary (baby) teeth, prevents cavity from getting worse

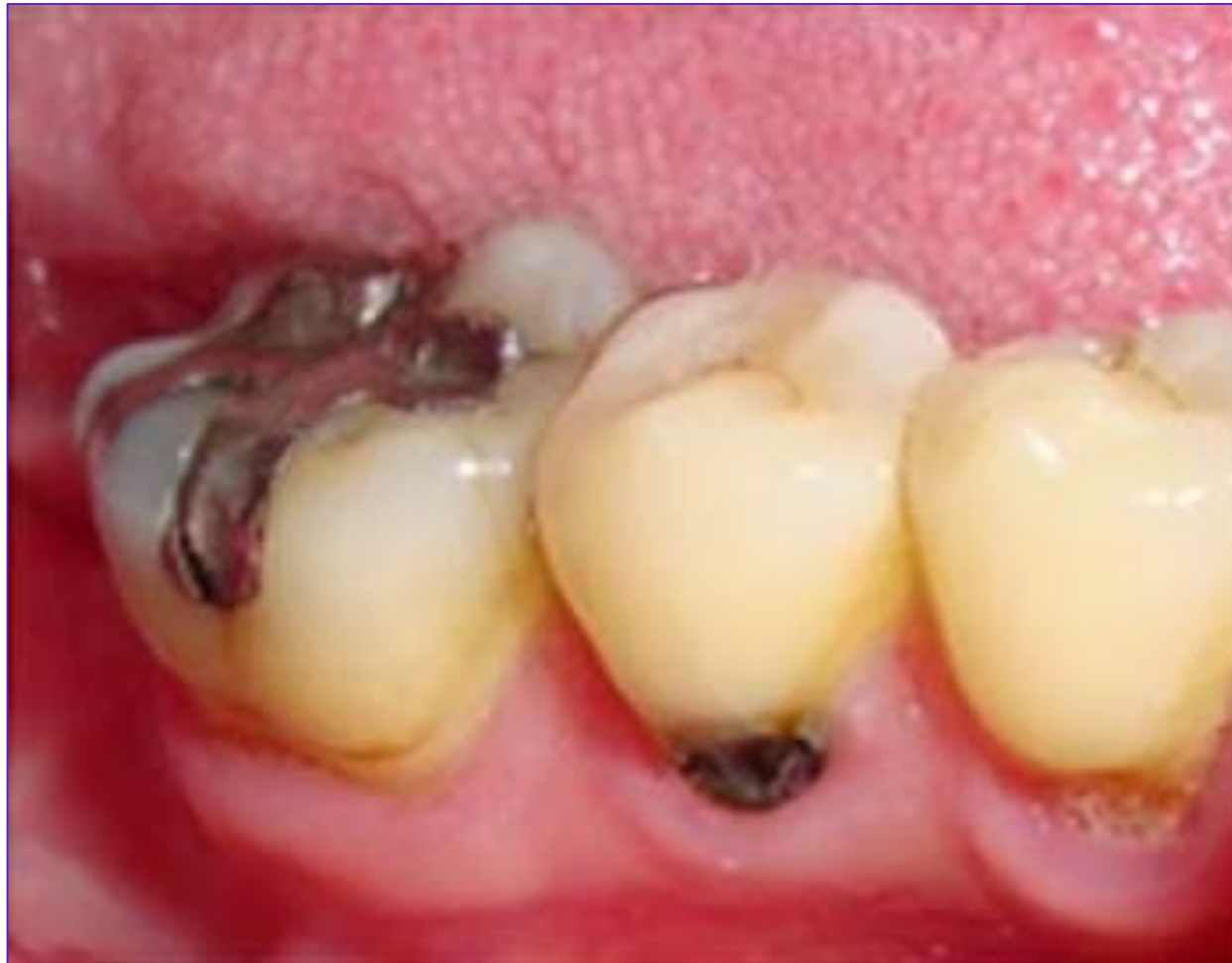SILVER DIAMINE FLUORIDE, JUST APPLIED



SILVER DIAMINE FLUORIDE, AFTER 1 DAY



SILVER DIAMINE FLUORIDE, AFTER 1 WEEK

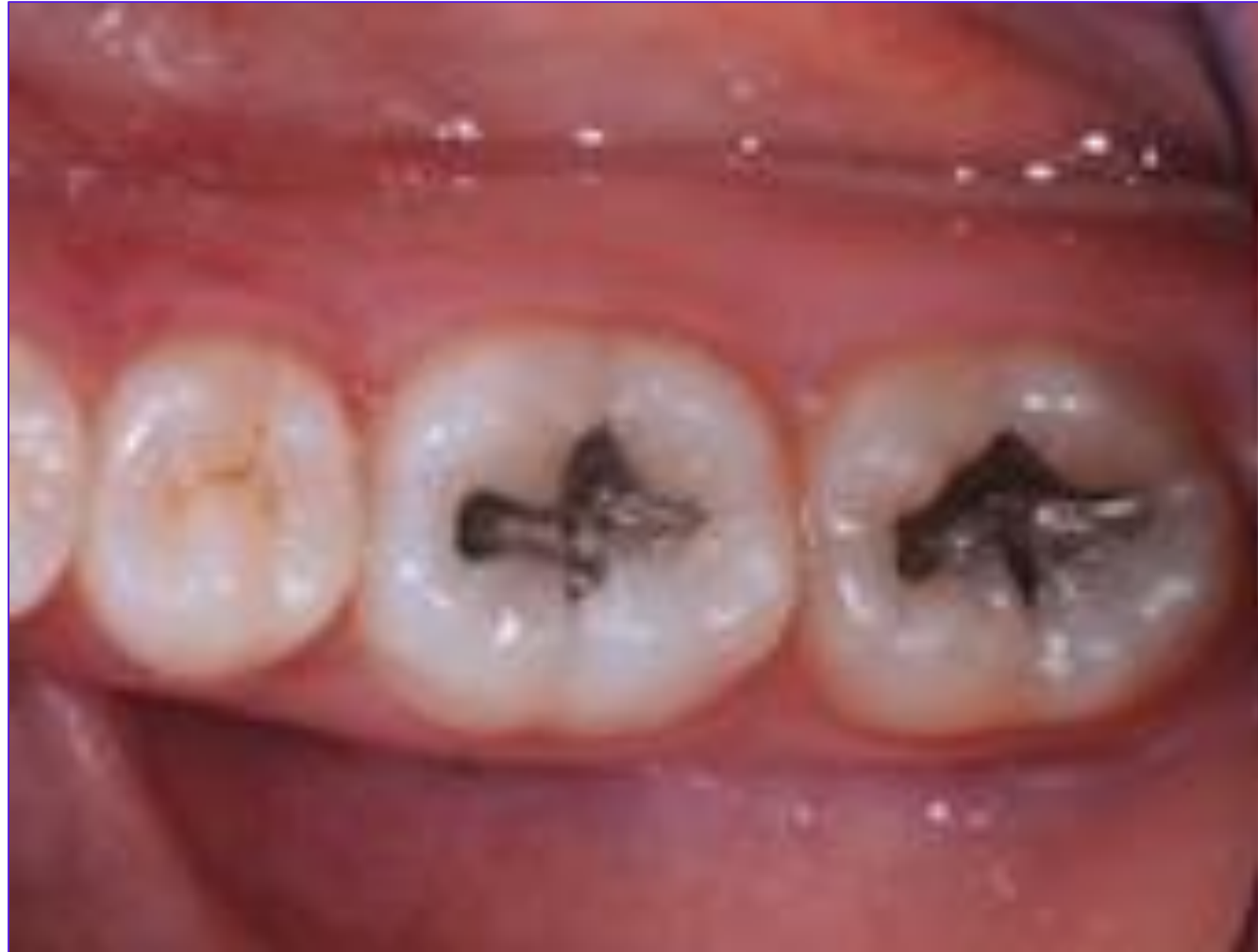



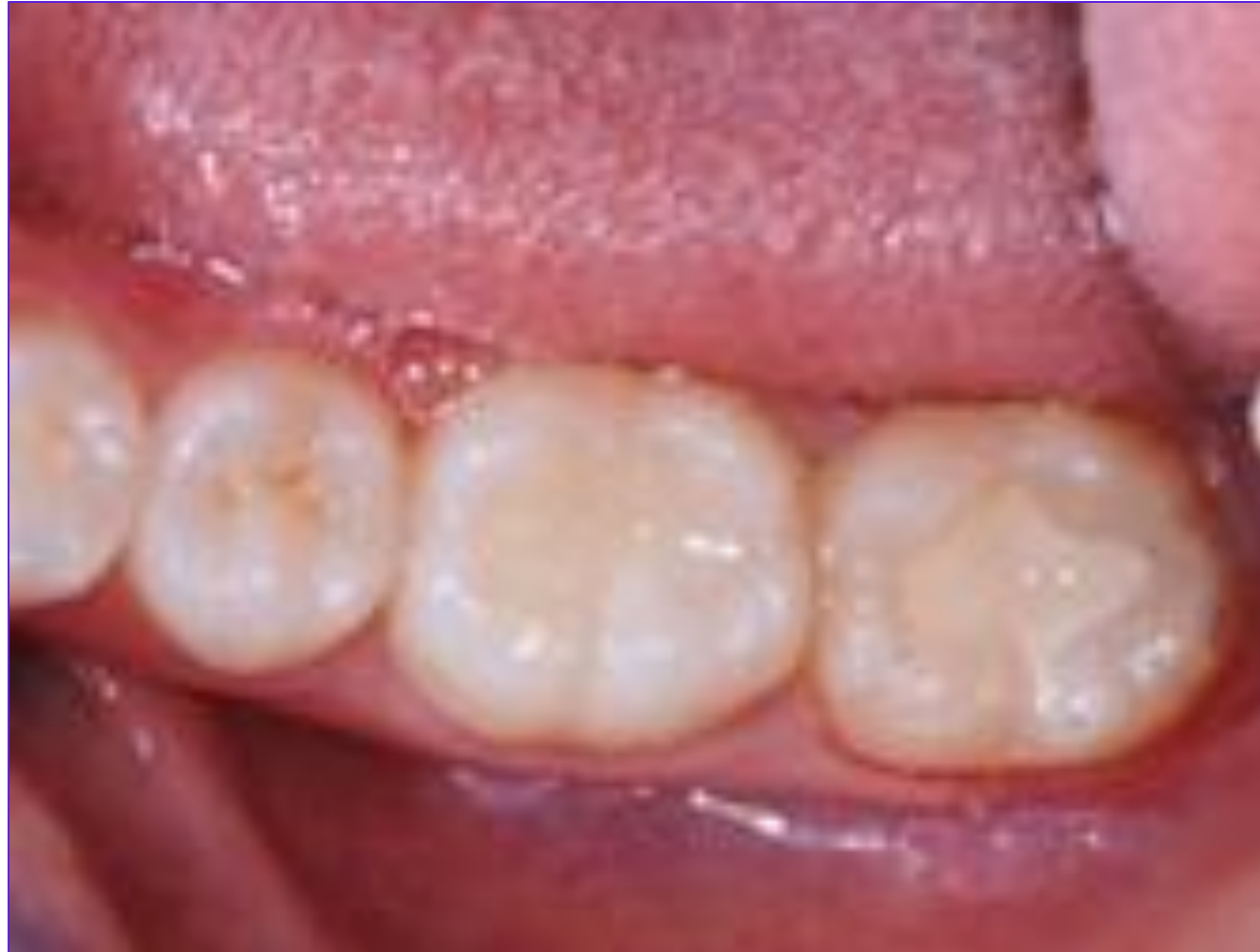INVASIVE TREATMENTS

- Amalgam filling – metallic mixture
- Composite filling – tooth-colored resin

AMALGAM FILLINGS



COMPOSITE FILLINGS

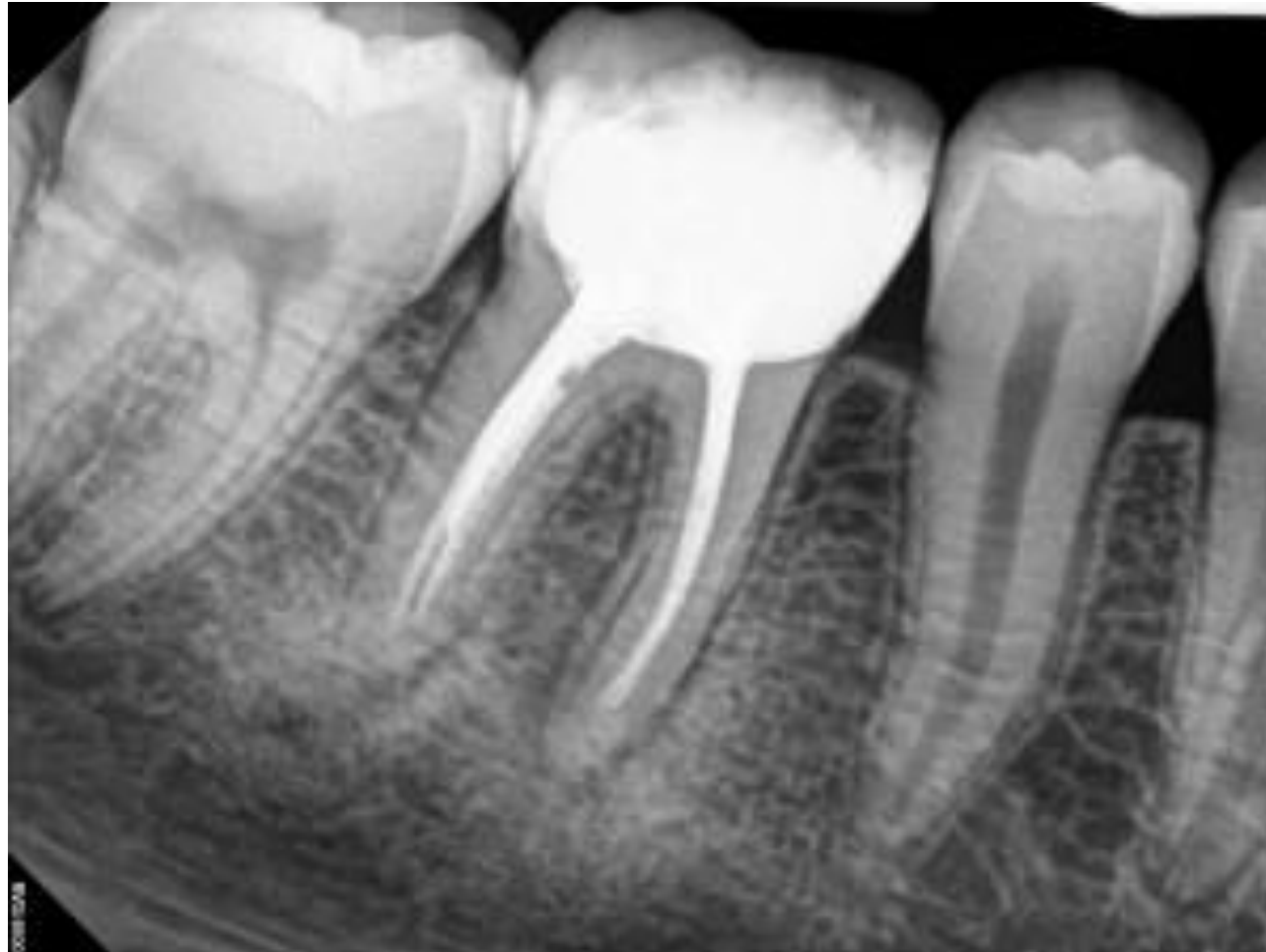



INVASIVE TREATMENTS, CONTINUED

- Root canal – removing nerve and filling space with non-reactive material
- Crown – porcelain, ceramic, or metallic, tooth-shaped
- Extraction – removing hopeless tooth

RADIOGRAPH OF ROOT CANAL



DIFFERENT TYPES OF CROWNS





PREVENTION

- Good oral hygiene – removes bacteria from tooth surfaces
- Professional dental cleaning – removes bacteria, removes calculus, applies fluoride treatments
- Fluoridated water



GINGIVITIS

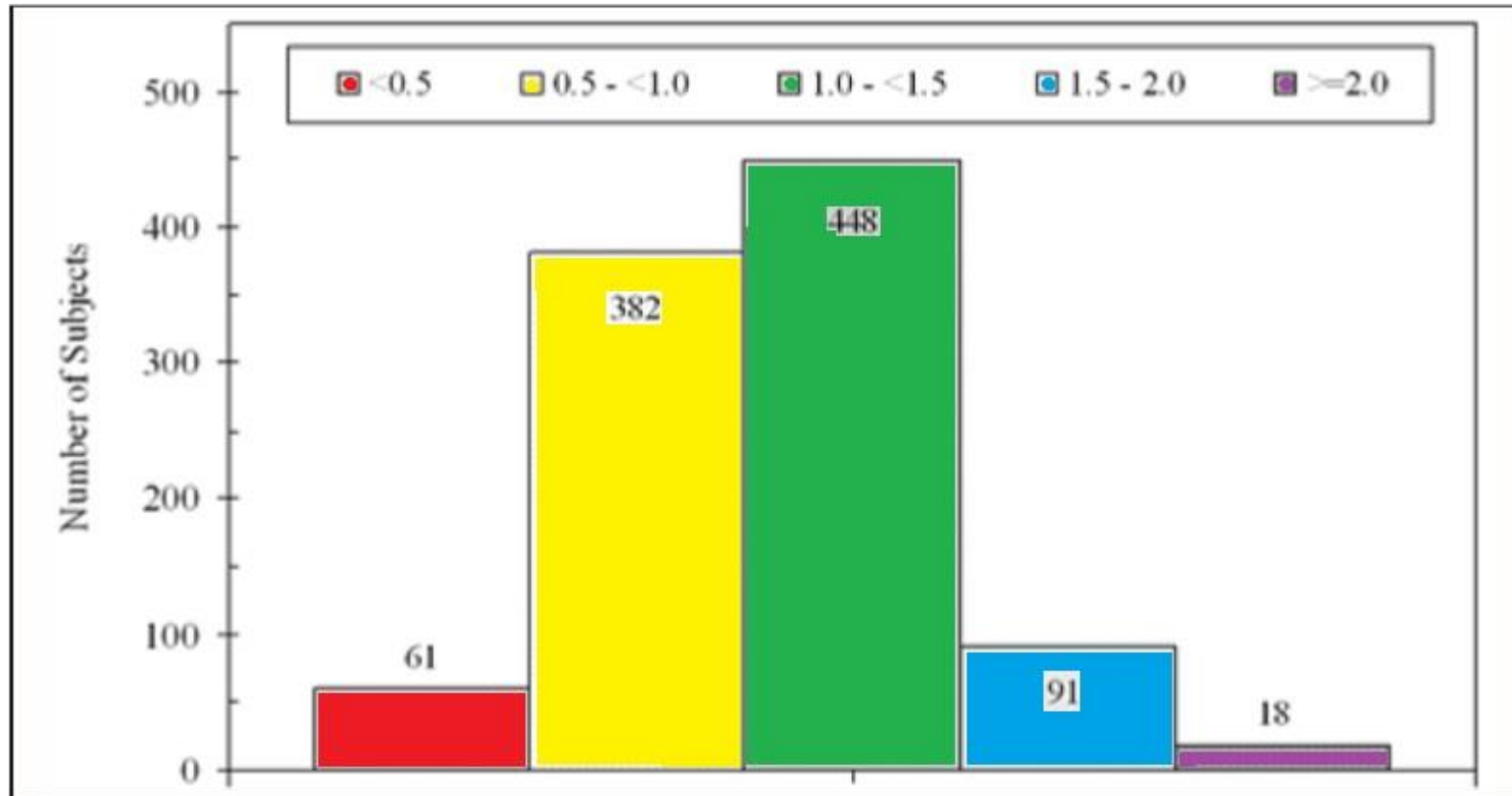
- What it is: gum irritation and inflammation due to plaque build-up
- Cause: poor oral hygiene, certain systemic factors, some medications

WHO HAS GINGIVITIS

- Tremendous variation in estimates, possibly due to numerous ways to quantify/qualify disease
- Li et al, 2010, majority (93%) of adults studied had some form of gingivitis

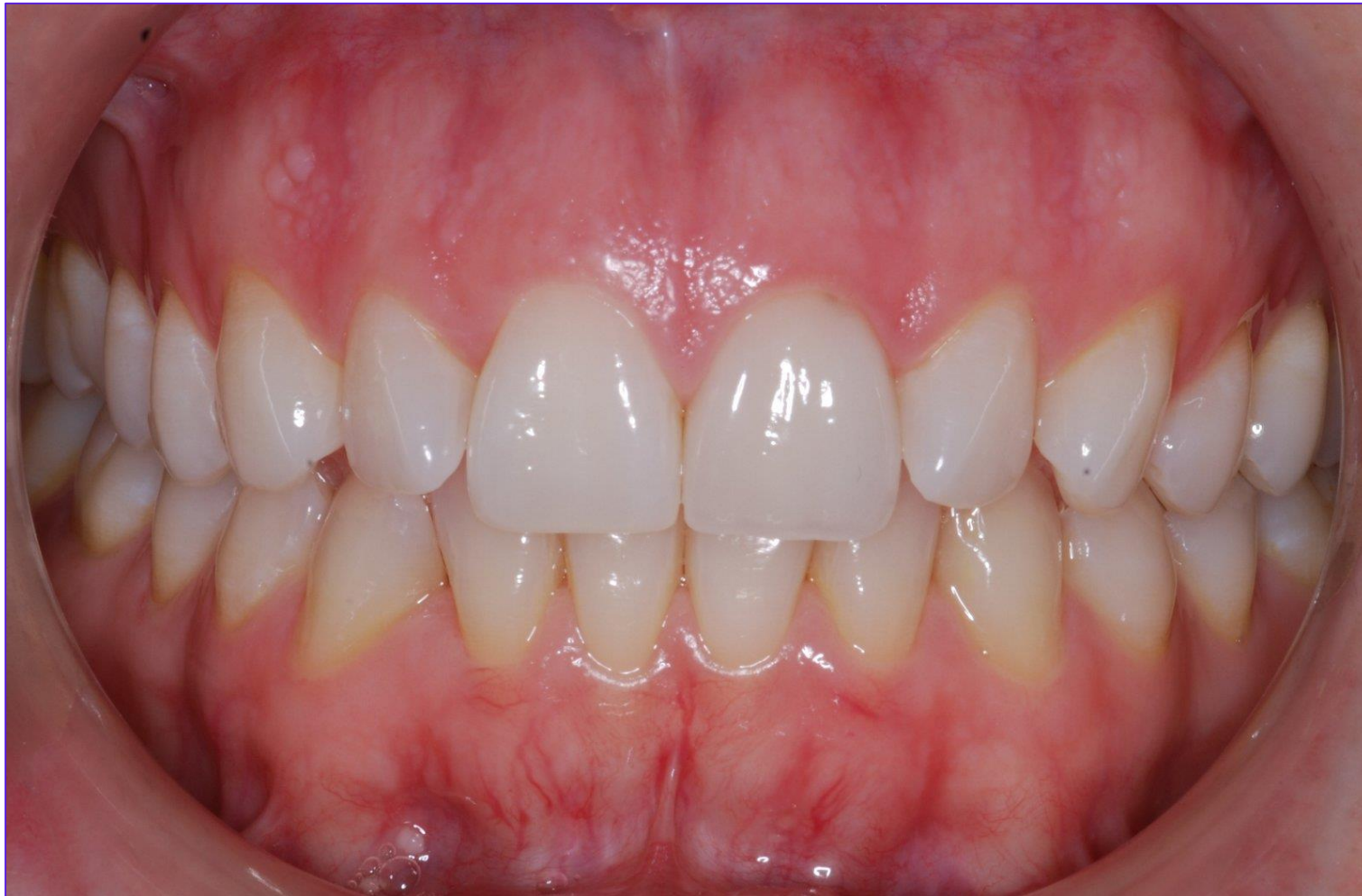Li, Yiming, et al. "Prevalence and severity of gingivitis in American adults." *American journal of dentistry* 23.1 (2010): 9.

GRAPH OF SUBJECTS' GINGIVITIS SCORES

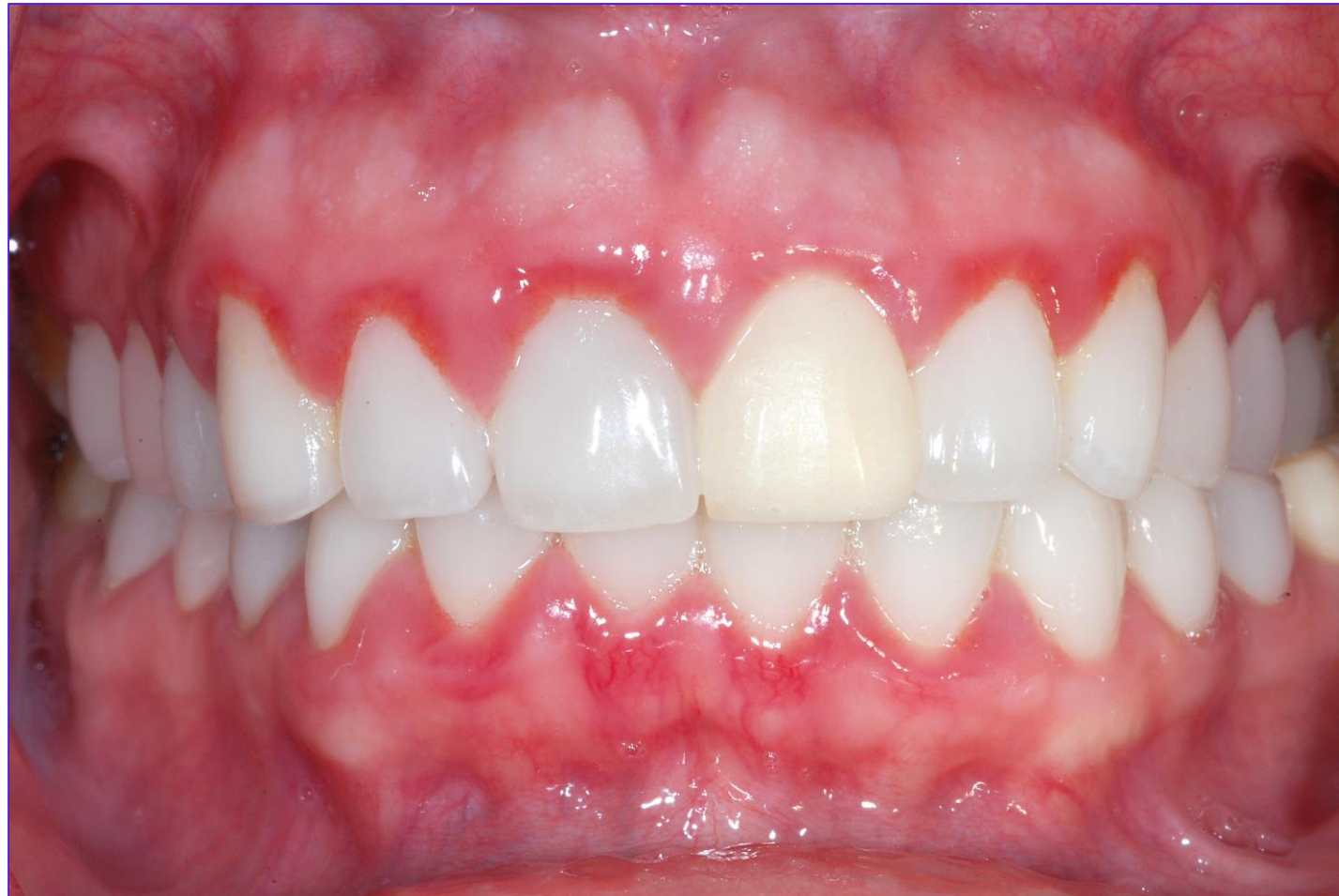

Li, Yiming, et al. "Prevalence and severity of gingivitis in American adults." *American journal of dentistry* 23.1 (2010): 9.

HEALTHY GUMS



GINGIVITIS





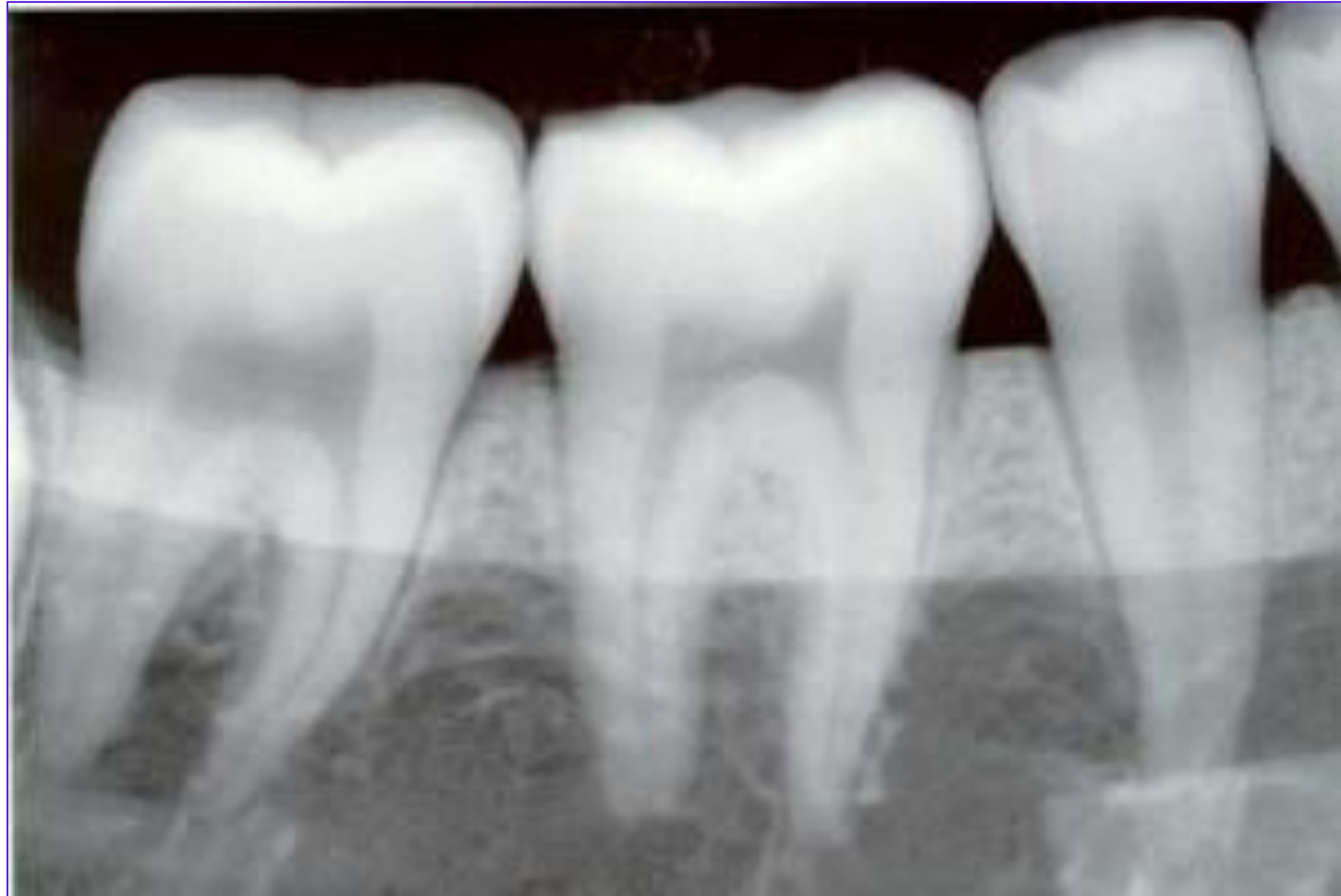
VISUAL SIGNS AND SYMPTOMS

- Redness
- Swelling
- Bleeding during brushing/flossing
- Bleeding during probing
- Radiographs – no evidence of bone loss

PROBING



NORMAL RADIOGRAPH



OTHER SIGNS AND SYMPTOMS

Tactile

- Gums are spongy, soft, indent when pressed with side of probe

Measurable

- Probing depths of 3-4mm



TREATMENT

At home

- Good oral hygiene habits – brushing, flossing, mouthwash

In office

- Professional deep cleaning
- Thorough patient education
- Prescription mouth rinses



PREVENTION

- Practice thorough oral hygiene
- See your dental hygienist or dentist regularly.



PERIODONTITIS

- What it is: inflammation of soft tissues with loss of tissue attachment and bone
- Cause: unresolved gingivitis that spreads through tissues to bone, poor oral hygiene
- Who is affected: CDC, 2012, almost 50% of U.S. adults 30 years and older have some form of periodontal disease

WHO HAS PERIODONTITIS

*THE AMERICAN ACADEMY OF PERIODONTOLOGY WARNS OF A SIGNIFICANT PUBLIC HEALTH PROBLEM

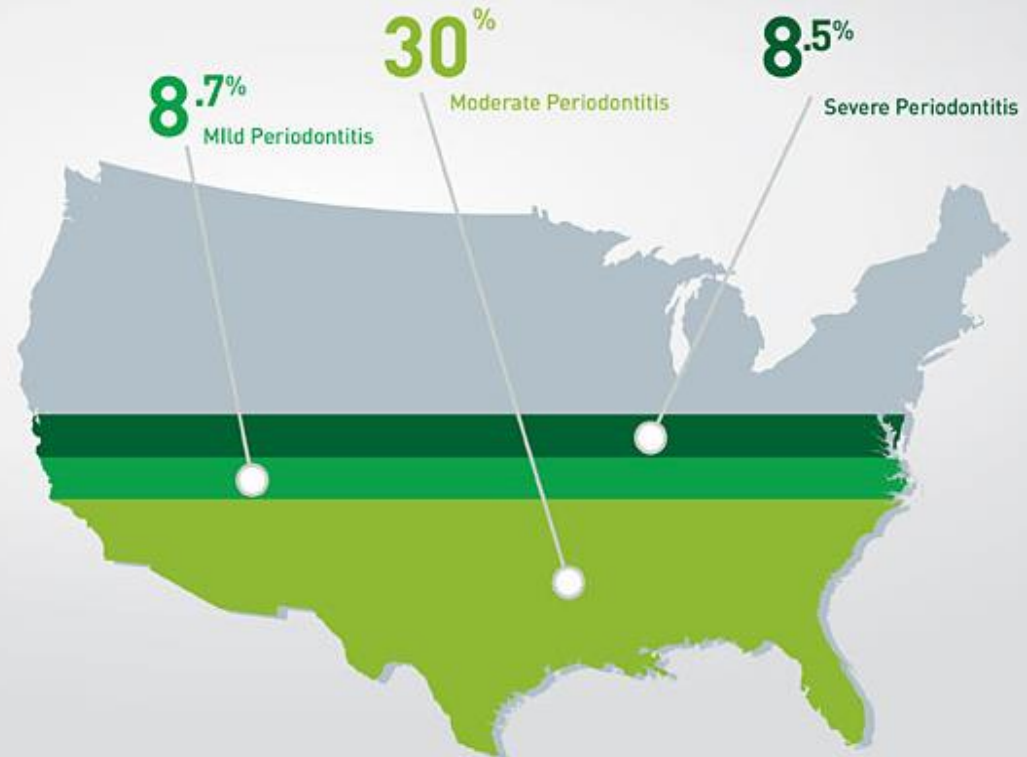
HALF OF AMERICAN ADULTS SUFFER FROM GUM DISEASE

47.2%
Have periodontitis

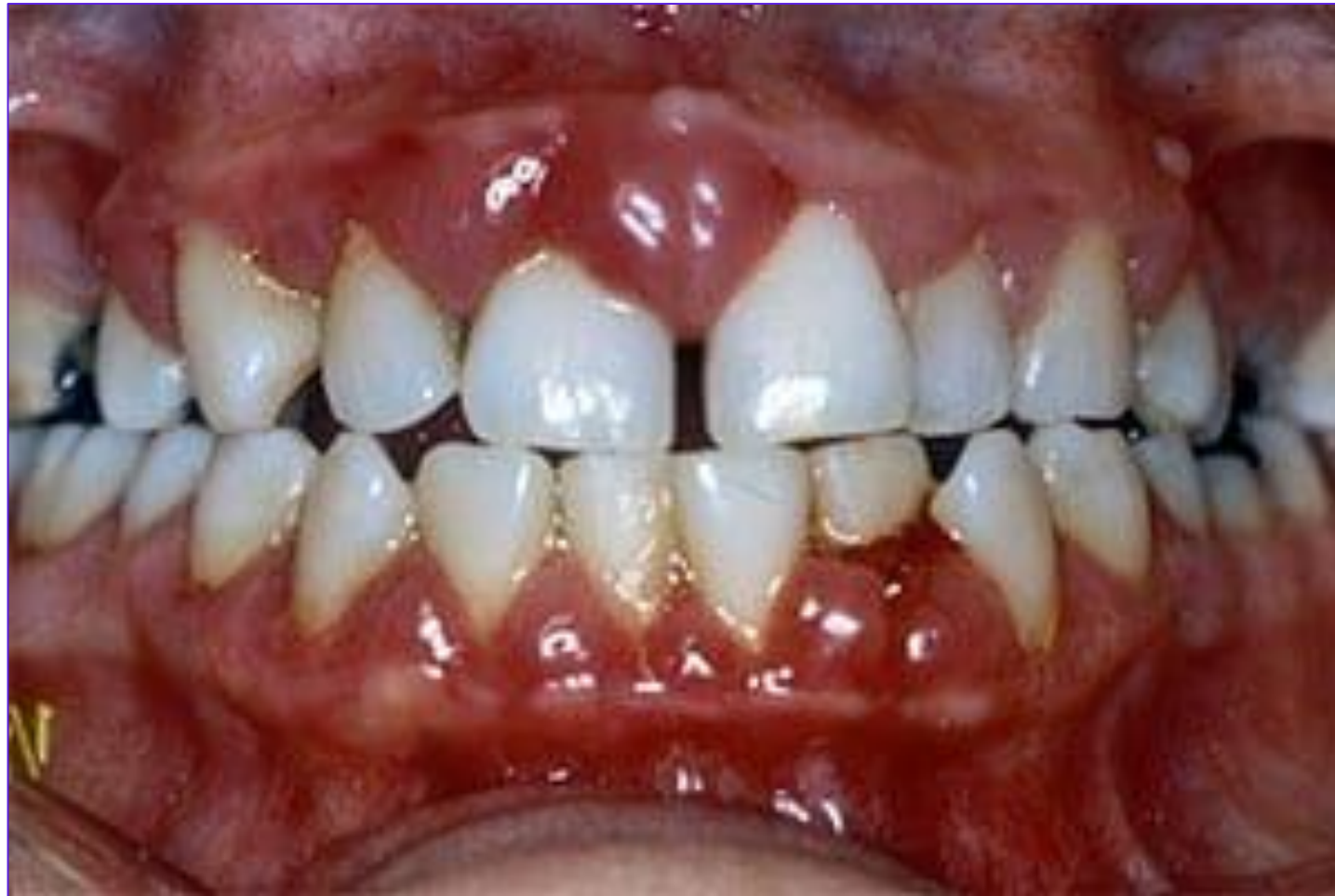THAT'S

64.7
Million

Adults 30 years
and older



PERIODONTITIS

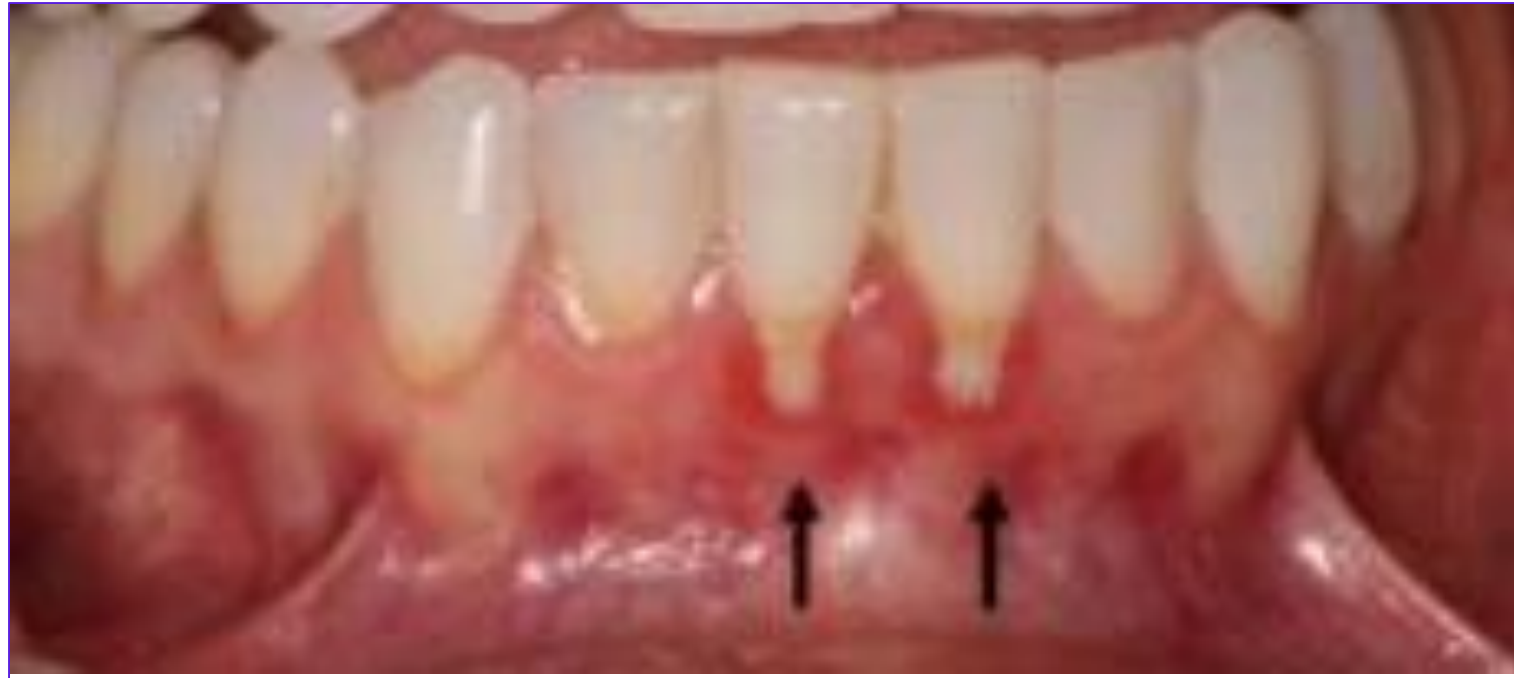



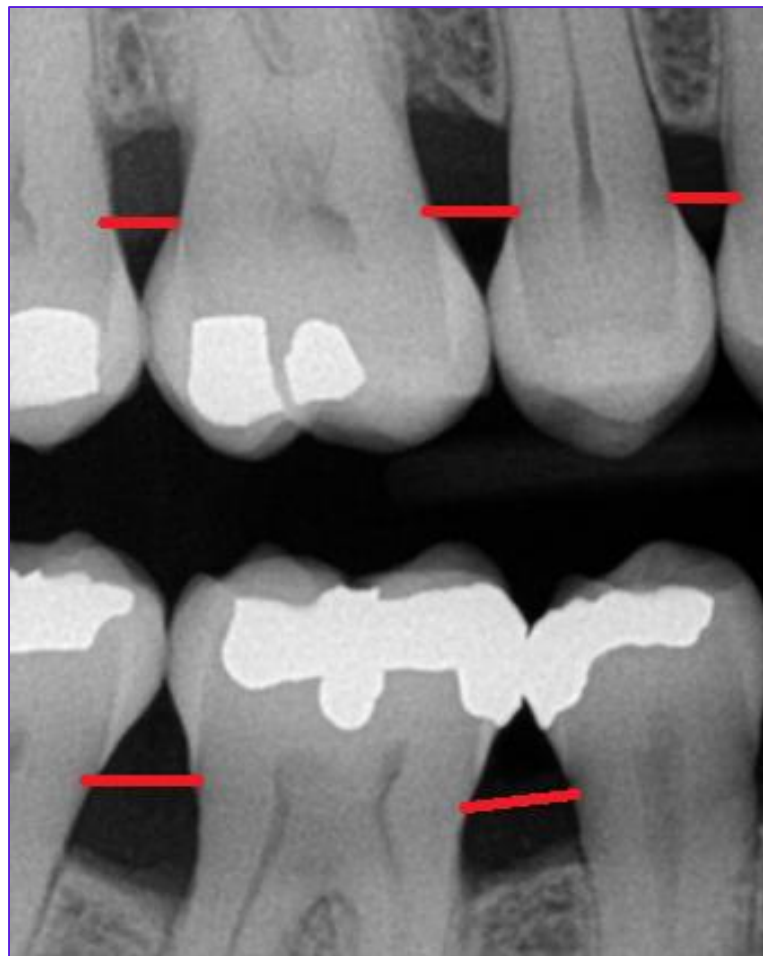
VISUAL SIGNS AND SYMPTOMS

- Very red gums
- Swelling
- Recession – gums start pulling away from tooth
- Radiographs – bone loss present

RECESSION



RADIOGRAPHIC BONE LOSS





OTHER SIGNS AND SYMPTOMS

Tactile

- Gums may be tender/painful

Olfactory

- Intense odor may be present

Measurable

- Pocket probing depths greater than 4mm

TREATMENT

At home

- Excellent oral hygiene

In office

- Deep cleaning
- Use of local and/or systemic medications
- Prescription antibiotics and/or mouth rinse
- Surgery to regrow bone or extend soft tissue
- Surgery to reduce pocket depth



PREVENTION

- Practice thorough oral hygiene
- See your dental hygienist or dentist regularly.

BIBLIOGRAPHY

“CDC: Half of American Adults Have Periodontal Disease.”
American Academy of Periodontology, 4 Sept. 2012,
www.perio.org/consumer/cdc-study.htm.

Iannucci, Joen M., and Laura Jansen Howerton. *Dental Radiography: Principles and Techniques*. Elsevier, 2017.

Li, Yiming, et al. "Prevalence and severity of gingivitis in American adults." *American journal of dentistry* 23.1 (2010): 9.



BIBLIOGRAPHY, CONTINUED

Weinberg, Mea A., et al. *Comprehensive Periodontics for the Dental Hygienist*. Pearson, 2015.

Wilkins, Esther M., et al. *Clinical Practice of the Dental Hygienist*. Wolters Kluwer, 2017.

PHOTOGRAPHIC SOURCE BIBLIOGRAPHY

“CDC: Half of American Adults Have Periodontal Disease.”
American Academy of Periodontology, 4 Sept. 2012,
www.perio.org/consumer/cdc-study.htm.

“Clinical Diagnostic Methods Part 2.” *Intelligent Dental*,
www.intelligentdental.com/2011/12/20/clinical-diagnostic-methods-part-2/.

Cotswold Periodontal Centre. “Check Your Gums.” *Perio Specialist*,
periospecialist.com/patients-section/check-your-gums/.



PHOTOGRAPHIC SOURCES BIBLIOGRAPHY, CONTINUED

“Crowns & Bridges.” *Mudrow Family Dental*,
www.mudrowfamilydental.com/general-cosmetic-dentistry/crowns-bridges/.

“Fighting Cavities Without A Dentist Drill.” *Ivanhoe Broadcast News, Inc.*, 28 Sept. 2017, www.ivanhoe.com/family-health/fighting-cavities-without-dentist-drill/.

PHOTOGRAPHIC SOURCES BIBLIOGRAPHY, CONT.

“Guided Tissue Regeneration: Options for Tooth Apparatus Loss.”
Metro West Orthodontics Periodontics,
www.metrowestdentalgroup.com/guided-tissue-regeneration-options-for-tooth-apparatus-loss/.


“How to Get Rid of Cavities/How to Reverse Cavities in Teeth.”
YouTube, YouTube, 6 Dec. 2016,
www.youtube.com/watch?v=Ww7pC2WkEkc.

“How to Read Dental X Rays or Radiographs for Cavities?” *DiseaseFix - Disease Information Center*, www.diseasefix.com/page/how-to-read-dental-x-rays-or-radiographs/3751/.

PHOTOGRAPHIC SOURCES BIBLIOGRAPHY, CONT.

“In Office Monitoring and Maintenance of Dental Implants.” *Dental Implant Life*, 5 Jan. 2012, www.dentalimplantlife.com/2012/01/in-office-monitoring-and-maintenance-of-dental-implants/.


Li, Yiming, et al. "Prevalence and severity of gingivitis in American adults." *American journal of dentistry* 23.1 (2010): 9.



PHOTOGRAPHIC SOURCES BIBLIOGRAPHY, CONT.

“Root Canal Tooth.” *Ross Family Dentistry*, www.ross-family-dentistry.com/toothachesandrootcanals/r9/.

“Symptoms – Gum Recession.” *Joseph R Nemeth DDS Associates*, drnemeth.com/symptoms-gum-recession/.



PHOTOGRAPHIC SOURCES BIBLIOGRAPHY, CONT.

“Tooth-Colored Composite Fillings.” *Olympic Dental Family and Cosmetic Dentistry*, olympicdental.net/tooth-colored-composite-fillings/.

“What Is Periodontitis.” *European Federation of Periodontology*, 3 Apr. 2018, www.efp.org/patients/what-is-periodontitis.html.

PHOTOGRAPHIC SOURCES BIBLIOGRAPHY, CONT.

Sandor, Kacso. "Neglected Teeth - Extended Cavities." *123RF*, www.123rf.com/photo_17049949_neglected-teeth-extended-cavities-.html.

Taglia Dentistry. "Gingivitis Causes & Treatment." *Taglia Advanced Dentistry*, 17 May 2017, www.tagliadentistry.com/blog/gingivitis-causes-treatment/.

Varun. "Dental Caries." *Junior Dentist*, 13 Mar. 2008, www.juniordentist.com/dental-caries.html.